

Chapter 19

Fetal Cardiac Malformations and Arrhythmias

Detection, Diagnosis, Management, and Prognosis

Mark Sklansky, MD

Over the years, as the practice of fetal ultrasonography has evolved, a consensus has formed among sonographers, radiologists, obstetricians, and maternal-fetal medicine subspecialists: screening for fetal heart disease deserves the dubious distinction of being one of the most challenging and least successful aspects of fetal ultrasonography.¹⁻³ Because of the challenges inherent with screening the fetus for congenital heart disease (CHD), the rate of prenatal detection of even severe forms of CHD remains disappointingly low.^{1,3-7} Furthermore, when a fetal heart defect or arrhythmia is suspected, many professionals feel uncomfortable with much more than referring the patient to someone else for further evaluation.

This chapter aims neither to make everyone involved with fetal ultrasonography into an expert fetal echocardiographer, nor to provide an exhaustive, encyclopedic review of the field of fetal cardiology; such detailed reviews may be found elsewhere.^{8,9} Instead, the chapter takes a distinctive clinical bent, aiming to help those involved with fetal cardiac imaging (1) to become better at screening the fetal heart for CHD, (2) to become better at diagnosing and evaluating common forms of fetal cardiac malformations and arrhythmias, (3) to understand the basic approach to fetal and neonatal management of the most common forms of fetal cardiac malformations and arrhythmias, and (4) to understand the general prognosis associated with the most common forms of fetal heart disease.

After a brief discussion of the epidemiology of fetal heart disease, this chapter reviews the basic approach to screening in low-risk pregnancies for fetal heart disease. The next section reviews the more detailed technique of formal fetal echocardiography in pregnancies at high risk for fetal CHD, including a description of the fetal presentation of fetal congestive heart failure (CHF) and a discussion of the potential role of three-dimensional (3D) fetal echocardiography. The last two sections discuss the diagnosis, management, and prognosis of the most common and clinically important forms of fetal cardiac malformations and arrhythmias.

Incidence of Congenital Heart Disease in the Fetus

CHD represents by far the most common major congenital malformation.^{10,11} Although most studies suggest an incidence of approximately

8 of 1000 live births,¹¹⁻¹³ this figure includes many forms of disease (e.g., secundum atrial septal defect [ASD], mild valvar pulmonary stenosis, and small muscular or membranous ventricular septal defects [VSDs]) that never will require either medical or surgical attention. In fact, 3 or 4 of every 1000 live newborn infants have some form of CHD that is likely to require medical if not surgical intervention.¹ Because cases of fetal heart disease, particularly those associated with aneuploidy or extracardiac malformations, may end in fetal demise, and because many VSDs may close spontaneously before birth,¹⁴ the incidence of CHD during the first and second trimesters should be considerably higher than the incidence at term.

At the same time, some forms of CHD probably have a higher incidence at term than during the first or early second trimesters. Many forms of CHD evolve dramatically from first trimester to term.^{15,16} Mild aortic or pulmonary valve stenosis, for instance, may evolve prenatally into severe forms of critical pulmonary or aortic stenosis or may even adversely affect ventricular development to the point of manifesting as hypoplastic left or right heart syndrome at term. Similarly, cardiac tumors such as cardiac rhabdomyomas or intrapericardial teratomas may not develop significantly until the second trimester,¹⁷ and they may continue to enlarge dramatically from mid-gestation to term. Ductal constriction or closure of the foramen ovale may not develop until late in gestation,¹⁸ and the same may be said for fetal arrhythmias, valvar regurgitation, myocardial dysfunction, and CHF.¹⁶

Risk Factors for Congenital Heart Disease in the Fetus

Inasmuch as most cases of CHD occur in pregnancies not identified as being at high risk,^{19,20} effective screening for CHD in low-risk pregnancies remains tremendously important. Nevertheless, many risk factors (fetal, maternal, and familial) for fetal heart disease have been identified (Tables 19-1, 19-2, and 19-3).²¹⁻³⁶ Some anomalies, such as omphalocele with diaphragmatic hernia and tracheoesophageal fistula,²⁶ cleft lip/palate,²⁵ aneuploidies such as trisomy,^{21,23,30} or maternal CHD,^{24,27,28,31,32} carry significantly increased risks for fetal heart disease. Other associations, such as a family history of CHD,^{24,34} many cases of maternal diabetes,^{23,36} fetal exposure to many of the known

TABLE 19-1 RISK FACTORS FOR FETAL HEART DISEASE**Fetal**

Abnormal visceral/cardiac situs
 Abnormal four-chamber view or outflow tracts
 Arrhythmia
 Aneuploidy
 Two-vessel umbilical cord
 Extracardiac structural malformation
 Intrauterine growth restriction
 Polyhydramnios
 Pericardial effusion/pleural effusion/ascites
 Twins
 Increased nuchal translucency thickness

Maternal

Systemic erythematosis
 Diabetes mellitus
 Phenylketonuria
 Viral syndrome (mumps, Coxsackie virus, influenza, rubella, cytomegalovirus)
 Congenital heart disease
 Teratogen exposure
 In-vitro fertilization?

Familial

First-degree relative with congenital heart disease
 First-degree relative with cardiac syndrome
 DiGeorge syndrome
 Long QT syndrome
 Noonan syndrome
 Marfan syndrome
 Tuberous sclerosis
 Williams syndrome

teratogens,^{23,29,35} and fetal ureteral obstruction or gastroschisis,²⁶ carry only moderately increased risks for CHD. Many syndromes (familial, sporadic, or related to known teratogens) convey variable risks for CHD.²³ Finally, additional risk factors for CHD will undoubtedly be recognized in the future. For instance, increased nuchal translucency thickness in the first trimester (10 to 14 weeks) represents an important newly discovered risk factor for fetal heart disease, even in the presence of normal fetal chromosomes.^{22,33} This subject is addressed in detail in Chapter 17.

A distinction should be recognized between “fetal risk factor for CHD” and “indication for fetal echocardiography.” Because not all risk factors for fetal heart disease are equal, the primary obstetrician or perinatologist should weigh the likelihood of fetal heart disease when considering whether further evaluation is indicated. However, the expertise of primary obstetricians, perinatologists, and radiologists, as well as pediatric cardiologists, in evaluating the fetal heart varies tremendously. Therefore, the determination of which pregnancies to refer for formal echocardiography should depend on the degree of added expertise in fetal cardiac imaging, management of fetal heart disease, and counseling for fetal heart disease offered by the consultant. Ultimately, the decision of whom to refer for formal fetal echocardiography should reflect both the perceived likelihood of fetal heart disease and the additional expertise anticipated from referral.

TABLE 19-2 EXTRACARDIAC STRUCTURAL MALFORMATIONS ASSOCIATED WITH FETAL HEART DISEASE**Central Nervous System**

Neural tube defect
 Hydrocephalus
 Absent corpus callosum
 Arnold-Chiari malformation
 Dandy-Walker malformation

Thoracic

Tracheoesophageal fistula
 Cystic adenomatoid malformation of the lung
 Diaphragmatic hernia

Skeletal

Holt-Oram syndrome
 Apert syndrome
 Thrombocytopenia/absent radii
 Ellis-van Creveld syndrome
 Fanconi syndrome

Gastrointestinal

Omphalocele
 Duodenal atresia
 Imperforate anus
 Gastroschisis

Urogenital

Dysplastic/absent kidney
 Horseshoe kidney
 Ureteral obstruction

TABLE 19-3 SUBSTANCES BELIEVED TO CAUSE FETAL HEART DISEASE

Anticonvulsants
 Valproic acid
 Carbamazepine
 Phenytoin
 Phenobarbital
 Warfarin
 Aspirin/ibuprofen
 Tricyclic antidepressants
 Lithium
 Alcohol
 Recreational drugs (including cocaine)
 Isotretinoin

Screening for Congenital Heart Disease in the Fetus

Background

The prenatal detection of CHD in the low-risk pregnancy has long represented the fetal sonographer’s Achilles’ heel.³⁷ Although CHD occurs more frequently than any other major congenital anomaly, the rate of detection has remained disappointingly low.^{1,3-7} This weakness

in fetal screening sonography represents a real problem. Not only is CHD responsible for most neonatal mortality from congenital malformations,¹⁰ but prenatal detection and diagnosis also can improve the outcome of fetuses and neonates with CHD.³⁸⁻⁴³ For these reasons, more improvement needs to be made in prenatal detection of the patient at low risk than in the detailed fetal diagnosis of CHD.^{5,19,44}

For years, those involved with fetal imaging have attempted to improve the prenatal detection of CHD. Soon after the development of two-dimensional (2D) fetal cardiac imaging, investigators proposed the four-chamber view (4CV) as an effective approach to screening the fetus for CHD.⁴⁵⁻⁴⁷ To this day, the 4CV has remained the standard of care for the screening fetal ultrasound evaluation of low-risk pregnancies, although probably not for much longer.^{2,48,49} In practice, the 4CV has not resulted in the high rates of detection initially anticipated.^{1,4,6,50-52}

To improve detection further, others have suggested that color flow imaging, performed along with the 4CV, could improve detection rates,⁵³ but this technique requires specialized expertise and equipment and probably adds little to the detection of major forms of CHD. On the other hand, there has been an important push toward attempting to include visualization of the outflow tracts along with the 4CV,⁵⁴⁻⁵⁹ because many defects (e.g., double-outlet right ventricle [DORV], tetralogy of Fallot [TOF], transposition of the great arteries [TGA], truncus arteriosus) can have normal-appearing 4CVs. Routine inclusion of the outflow tracts has been somewhat problematic, however, in part because the outflow tracts, unlike the 4CV, do not reside in a single plane. Nevertheless, inclusion of outflow tracts along with the 4CV for the low-risk standard fetal ultrasound evaluation makes sense and is swiftly becoming the standard of care.^{2,48,49}

More recently, multiple investigators have suggested that 3D imaging, wherein volumes may be acquired within seconds and subsequently interactively reviewed, allowing the display of virtually any plane, may facilitate and improve the evaluation of both the 4CV and the outflow tracts.⁶⁰⁻⁶² However, image resolution with 3D imaging remains low, and considerable expertise currently is required to evaluate volume data sets, despite a wealth of evolving algorithms and display techniques aimed at facilitating and improving analysis.⁶⁰⁻⁶⁴

Despite these developments, prenatal fetal cardiac anatomy screening remains flawed, for several reasons. First, the practice of prenatal screening for CHD remains heavily dependent on both the expertise of the sonographer^{3,65} and the quality of the equipment. Second, and equally important, effective screening requires an experienced reviewer to evaluate the fetal heart.⁵⁵ And third, although it makes sense to evaluate static fetal structures as still-frame images, it does not make sense—and does not work—to evaluate the heart as a single still-frame image of the 4CV, or even as a series of still-frame images of the 4CV and outflow tracts.³⁷

For these reasons, the beating 4CV (plus outflow tracts) should supplant the 4CV as the centerpiece of screening the fetus for CHD.³⁷ Visualization of valve and myocardial motion facilitates and enhances the evaluation of cardiac structure^{4,66} and makes reviewers less likely to miss a major structural defect. Ideally, screening should also include evaluation of both outflow tracts; however, the addition of just the left ventricular outflow tract (LVOT) would probably effectively detect most major anomalies typically missed with 4CV imaging alone.⁵⁶ The following paragraphs describe the routine (second-trimester) evaluation of low-risk pregnancies for fetal heart disease; descriptions of first-trimester evaluation of the fetal heart may be found elsewhere.^{15,67-70}

Technique

Extracardiac Evaluation

Prenatal screening for CHD should begin with an evaluation for extracardiac abnormalities associated with CHD. The umbilical cord should have three vessels; the heart and stomach should both be on the fetal left (above and below the diaphragm, respectively); and there should be no ascites (Fig. 19-1) or pericardial or pleural effusions. A trivial amount of pericardial fluid may normally be seen adjacent to the right and left ventricular free walls.⁷¹ Abnormalities of any of these findings should raise the suspicion for CHD and prompt more than just a routine evaluation.

Beating Four-Chamber View

The 4CV (Figs. 19-2 and 19-3) always deserves a close, detailed evaluation, even as part of a general screening fetal ultrasound study. In fact, given the current low rates of prenatal detection of CHD,^{1,3-7} the 4CV probably deserves more attention than it has been receiving. Evaluation of the beating 4CV should assess situs, size, symmetry, structure, and squeeze.

SITUS

The heart should be located within the left thorax, with the apex directed approximately 45 degrees to the left. Hearts on the right (dextrocardia), in the middle (mesocardia), or with the apex directed toward the left (left axis deviation)⁷² have all been associated with CHD. Moreover, should the space around the heart be filled with fluid, either circumferentially or with a depth of greater than 2 mm, further evaluation may be indicated.⁷¹

SIZE

The heart should occupy no more than approximately one third of the cross-sectional area of the thorax.⁷³ Alternatively, the circumference of the fetal heart should be no more than approximately half the transverse circumference of the thorax. However, no quantitative threshold outperforms an experienced eye. An enlarged fetal heart, by

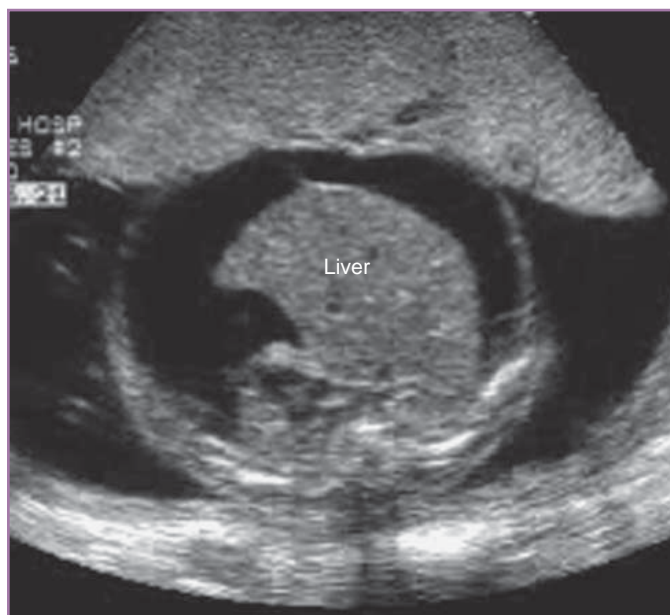


FIGURE 19-1 Fetal ultrasonographic image of severe ascites.

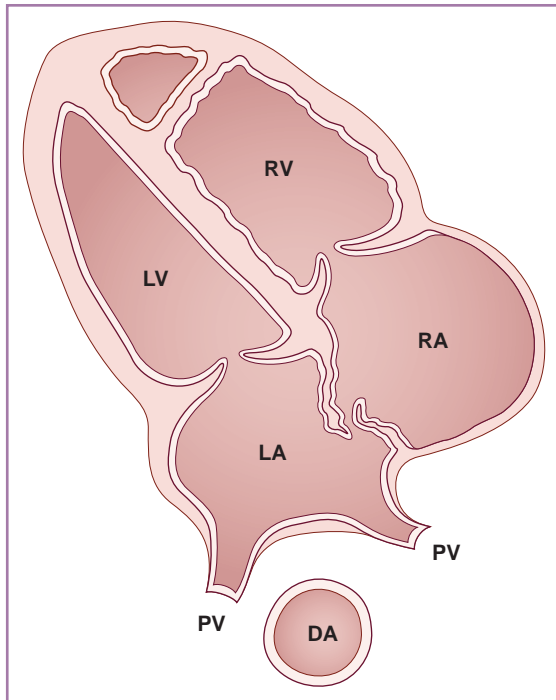


FIGURE 19-2 Schematic diagram of fetal four-chamber view. The right side of the heart appears slightly larger than the left side. The pulmonary veins (PV) enter the left atrium. The flap of the foramen ovale resides within the left atrium. The tricuspid valve inserts onto the ventricular septum slightly apical to the mitral valve insertion. The moderator band characterizes the right ventricular apex. Both ventricles contribute to the cardiac apex. DA, descending aorta; LA, left atrium; LV, left ventricle; RA, right atrium; RV, right ventricle. (Diagram courtesy of Irving R. Tessler, M.D.)

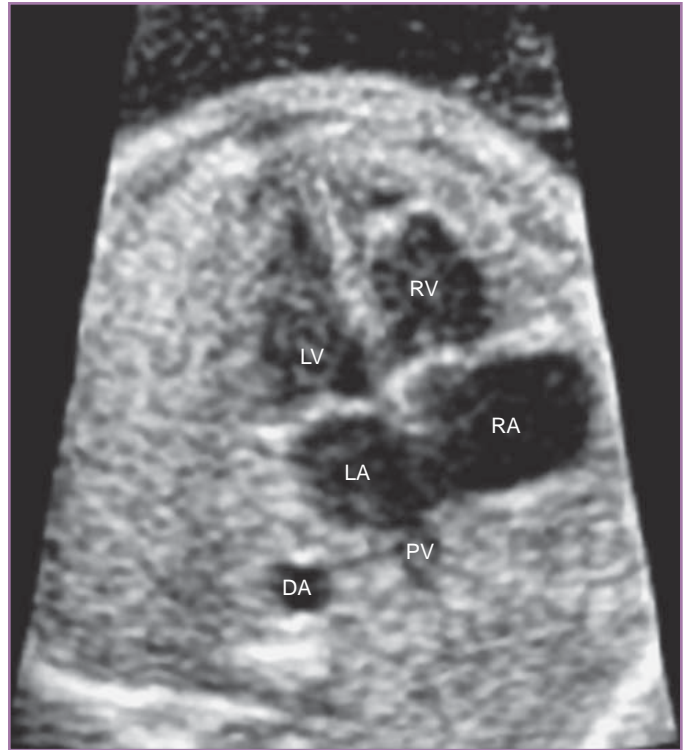


FIGURE 19-3 Fetal echocardiographic image of four-chamber view. Compare with Figure 19-2. The right side of the heart appears slightly larger than the left. A right-sided pulmonary vein (PV) drains into the left atrium (LA). The tricuspid valve inserts onto the ventricular septum slightly more apically than does the mitral valve. The moderator band characterizes the right ventricular apex. Both ventricles contribute to the cardiac apex. DA, descending aorta; LV, left ventricle; RA, right atrium; RV, right ventricle.

any means of measurement, should be considered a strong indicator of CHD and should prompt a more detailed evaluation.

SYMMETRY

The right and left sides of the fetal heart should appear generally symmetrical, with the right side slightly larger. During the third trimester, this right-sided predominance may become more pronounced.⁷⁴ If the left side of the heart appears larger than the right, or if the right side appears substantially larger than the left, further evaluation may be prudent.

Frequently, there is a question as to whether the right side is enlarged or the left side is small. Commonly, it may be a little of both, with fetal cardiac output simply redistributing. In other cases, however, the pathology is truly one-sided. The more important questions to consider may be (1) why is there an abnormal ratio between the right and left sides of the heart, and (2) what is the primary lesion?

STRUCTURE

Even for the purposes of screening for CHD, several aspects of the structure of the 4CV should be evaluated. First, the flap of the foramen ovale should be visualized deviated into the left atrium. This flap may not be well visualized, but certainly a flap that is deviated toward the right atrium should raise the concern for right-sided volume or pressure overload and prompt further evaluation. Second, the lowest portion of the atrial septum, just above the insertion point of the mitral valve, should always be visualized. Third, the septal leaflet of

the tricuspid valve should attach to the ventricular septum slightly more toward the apex than the septal leaflet of the mitral valve does. In practice, this normal offset may be subtle, difficult to appreciate, and honestly not critical to note for the purposes of screening for CHD.

Fourth, the mitral and tricuspid valves should be thin and delicate, with the tricuspid valve slightly larger than the mitral valve, and the valves should open symmetrically during diastole. Fifth, the left ventricle (aligned with the left atrium) should be smooth walled and should extend to the apex. The right ventricle should appear more heavily trabeculated and should extend toward the cardiac apex along with the left ventricle. Finally, the ventricular septum should appear intact with 2D imaging.

SQUEEZE

The 4CV, even for the purposes of screening for CHD, should be evaluated with the heart beating. The heart rate should range roughly between 120 and 160 beats/min, with no pauses and no skipped or extra beats, other than transient bradycardia during deep transducer pressure. The mitral and tricuspid valves should open and close symmetrically, and both ventricles should squeeze well. Abnormalities of rhythm, valvar function, or myocardial motion may reflect important forms of fetal heart disease and may be overlooked with evaluation of only still-frame images.³⁷

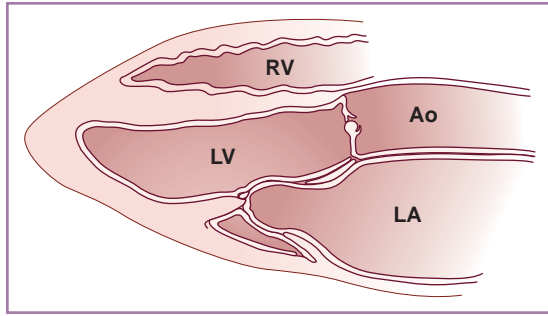


FIGURE 19-4 Schematic diagram of fetal left ventricular long-axis view. Note that it is preferable to obtain the image perpendicular to left ventricular outflow tract. Ao, aorta; LA, left atrium; LV, left ventricle; RV, right ventricle. (Diagram courtesy of Irving R. Tessler, M.D.)

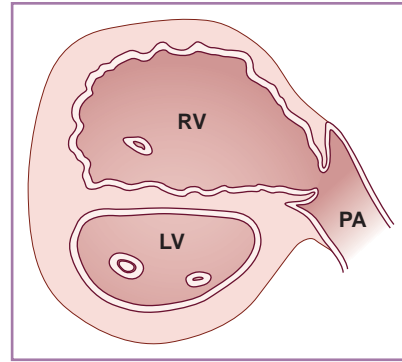


FIGURE 19-6 Schematic diagram of right ventricular outflow tract crossing view. LV, left ventricle; PA, main pulmonary artery; RV, right ventricle. (Diagram courtesy of Irving R. Tessler, M.D.)

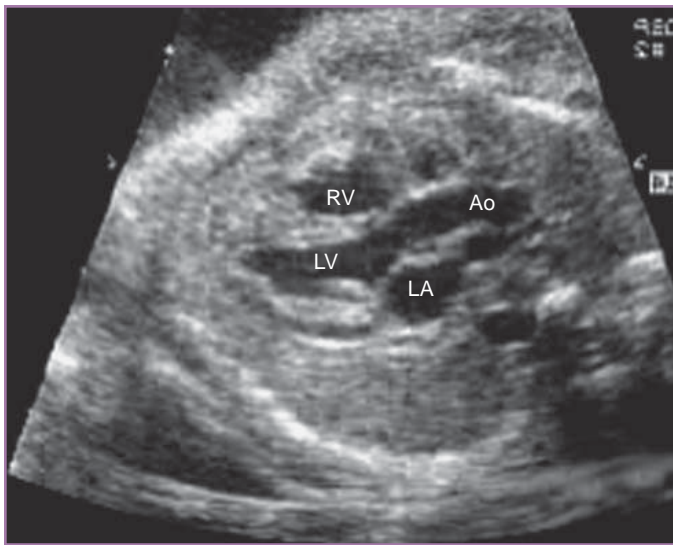


FIGURE 19-5 Fetal echocardiographic image of left ventricular long-axis view. Compare with Figure 19-4. Ao, aorta; LA, left atrium; LV, left ventricle; RV, right ventricle.

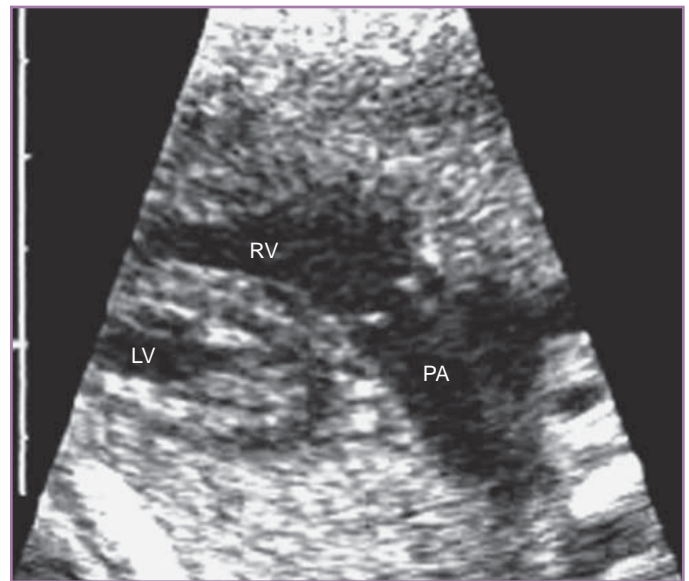


FIGURE 19-7 Fetal echocardiographic image of right ventricular outflow tract crossing view. Note that the pulmonary artery aims to the left of the spine. Compare with Figure 19-6. LV, left ventricle; PA, main pulmonary artery; RV, right ventricle.

Outflow Tracts

Ideally, prenatal screening for CHD should include visualization of both outflow tracts. In practice, appropriate evaluation of the outflow tracts may be more challenging than visualization of the 4CV. Nevertheless, because of the ability of the outflow tract views to detect major forms of CHD not visualized with the 4CV, a serious attempt should be made to evaluate the LVOT at the very least, and evaluation of both outflow tracts is becoming the standard of care.^{2,48,49}

Slight angulation of the transducer cephalad from the 4CV should demonstrate the aortic valve and ascending aorta arising from the left ventricle (Figs. 19-4 and 19-5). The aortic valve should appear thin and delicate. The ventricular septum should be noted to extend, uninterrupted, from the cardiac apex all the way to the lateral aspect of the ascending aorta. The ascending aorta, or aortic root, should point toward the right of the spine. The left ventricular long-axis view should be able to detect most forms of CHD involving the outflow tracts.⁵⁶ However, with just slight further cephalic angulation of the transducer, the right ventricular outflow tract, or RVOT (pulmonary valve and pulmonary artery), can be visualized arising from the right ventricle

and crossing the aortic root (Figs. 19-6 and 19-7). The pulmonary valve should be thin and delicate, and the pulmonary valve and main pulmonary artery should be slightly larger than the aortic valve and aortic root. The main pulmonary artery should point to the left of the spine.

Prenatal Screening Using Three-Dimensional Imaging

Although the current standard for screening the low-risk pregnancy for CHD uses 2D imaging, 3D imaging may ultimately facilitate the prenatal detection of CHD by allowing virtual⁶⁰ or automated^{63,75} evaluation of the entire fetal heart after a simple, short acquisition. When desired, volume data sets may be transmitted electronically to experts at remote locations, who can perform a virtual examination as if actually scanning the patient themselves.⁷⁶ Ultimately, 3D fetal cardiac imaging may make acquisition of fetal cardiac data sets less

dependent on time and operator skill and facilitate evaluation of the 4CV and outflow tracts offline.^{60,77} 3D fetal cardiac imaging is discussed further in the next section, which covers fetal echocardiography in high-risk pregnancies.

Technique of Fetal Echocardiography

Detailed fetal echocardiography in the pregnancy at high risk for CHD provides an in-depth and comprehensive evaluation of fetal cardiovascular structure and function.⁷⁸ In experienced hands, and particularly when performed beyond 18 weeks' gestation, fetal echocardiography has been shown to have high degree sensitivity for almost all forms of fetal heart disease.^{19,79,80} First-trimester fetal echocardiography, performed between 10 and 14 weeks' gestation either transvaginally or transabdominally, does not have the same degree of sensitivity for CHD as second-trimester imaging, in part because many forms of CHD evolve significantly between the late first trimester and term (e.g., aortic and pulmonary valvar stenosis, ventricular hypoplasia, valvar regurgitation, arrhythmias, cardiac tumors, restriction of the ductus arteriosus or foramen ovale).^{16,81,82} Although first-trimester fetal echocardiography undoubtedly will have an increasing clinical role as the technique's resolution improves,^{15,67-70,83} it is not discussed here in any further detail. Instead, this section reviews the technique of fetal echocardiography as performed transabdominally beyond 16 to 18 weeks' gestation. Solely to optimize image quality, fetal echocardiography optimally should be performed between 22 and 28 weeks' gestation. However, because earlier diagnosis may be desired for various management and emerging therapeutic options, fetal echocardiography should be performed generally between 18 and 22 weeks' gestation.

Formal fetal echocardiography involves evaluation of the fetal heart and cardiovascular system using several modalities: 2D imaging, color flow imaging, spectral/continuous wave Doppler evaluation, quantitative assessment of ventricular function, and 3D imaging. In practice, the fetal heart and cardiovascular system is probably best evaluated in an anatomically systematic fashion, using various modalities in combination for each anatomic component of the evaluation. However, the order in which individual components of the evaluation are performed may vary with case-specific clinical and imaging considerations.

Various quantitative measurements^{8,9,84-94} may be performed if an abnormality is suspected, if doubt remains regarding normalcy, or if measurements for a database are desired. Spectral Doppler echocardiography should routinely be used to assess flow across vessels or valves with suspected pathology.^{84,86,91-94} Any structure that appears small or large should be measured several times, with the best-guess measurement plotted on nomograms according to gestational age.⁹⁵⁻¹⁰⁰ Color flow imaging, which is exquisitely sensitive to valvar regurgitation, flow through small VSDs, and pulmonary/systemic venous returns, should be used routinely to demonstrate normalcy and to assess pathology. More sophisticated tissue Doppler studies^{89,101,102} or other quantitative means of evaluation of ventricular diastolic⁹¹⁻⁹⁴ or combined diastolic/systolic^{87,88} function may be used in special circumstances. This section describes a clinical approach to the formal fetal echocardiographic evaluation, with an emphasis on the importance of routine 2D and color flow imaging. Readers should note that this approach might be somewhat less rigorous and comprehensive than that described in previously published guidelines,⁷⁸ but it may also be more clinically practical in many settings.

General Imaging

The formal fetal echocardiogram begins with a determination of the number of fetuses, their levels of activity, their respective positions, and their gestational ages. The number of fetuses and their respective positions matter because the lie, late in the third trimester, may affect delivery plans. With multiple-gestation pregnancies, each fetus should undergo its own detailed fetal echocardiogram, and noting the fetal lie or position helps to distinguish one fetus from another. Gestational age determination (1) enables assessment of fetal growth, (2) may affect counseling or management strategies, and (3) allows assessment of cardiac structures that vary in appearance with gestational age.

Umbilical Cord

Next comes evaluation of the umbilical cord (Fig. 19-8). Spectral Doppler evaluation of the umbilical artery provides information on placental resistance, which may affect fetal cardiovascular function and reflect overall fetal well-being. In cases of suspected placental pathology, calculation of a pulsatility index enables a quantitative assessment of placental resistance. Doppler evaluation of the umbilical vein in free-floating cord is most useful in cases of suspected fetal heart failure.⁸⁶ Normally, the umbilical venous waveform pulsates in response to fetal breathing, but it should not vary with the fetal cardiac cycle. Pulsatile flow in the free-floating umbilical cord, reflecting fetal cardiac contractions, suggests markedly elevated fetal right atrial pressure and represents a manifestation of significant CHF.¹⁰³

Hydrops

Initial evaluation of the fetus itself should assess for the presence of fluid accumulation suggestive of CHF. Normally, no more than a trivial (loculated and <2 mm) pericardial effusion should be present.⁷¹ Greater accumulation of pericardial fluid (circumferential or >2 mm) or the presence of any pleural fluid or ascites (see Fig. 19-1) should be considered abnormal, with a differential diagnosis including CHF, myopericarditis, viral infection, anemia, and aneuploidy.

Visceroatrial Situs

Following the determination of fetal number, position, gestational age, umbilical waveforms, and presence or absence of hydrops, attention should be directed toward the structure and function of the fetal cardiovascular system itself. This assessment should begin with an




FIGURE 19-8 Spectral Doppler display of flow within free-floating umbilical cord. UA, umbilical artery; UV, umbilical vein.

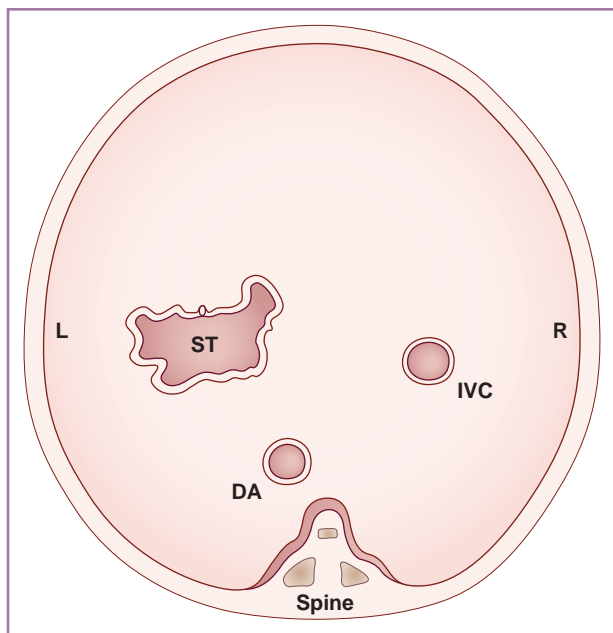


FIGURE 19-9 Schematic diagram of abdominal situs view. DA, descending aorta; IVC, inferior vena cava; L, fetal left; R, fetal right; ST, stomach. (Diagram courtesy of Irving R. Tessler, M.D.)

abdominal assessment of visceral situs (Figs. 19-9 and 19-10). Transverse imaging of the abdomen should demonstrate the descending aorta, in cross section, just anterior and slightly leftward of the spine. The stomach should be anterior and leftward, and the inferior vena cava (IVC) and liver should both be anterior and rightward. A prominent vein (usually the azygos) should not be visualized posterior to the descending aorta. Angulation of the probe from transverse to sagittal imaging should demonstrate the IVC draining into the right atrium. Finally, transverse imaging of the thorax should demonstrate the heart on the left, with the apex directed anteriorly and leftward. Abnormalities of any of these features should prompt further evaluation for situs abnormalities (asplenia or polysplenia) or associated CHD or both.

Beating Four-Chamber View

Central to screening for CHD, the 4CV also represents a critically important aspect of the formal fetal echocardiogram.^{8,9,104} As with screening, detailed fetal echocardiography begins by demonstrating the fetal heart to be in the left thorax with the apex directed approximately 45 degrees to the left (see Figs. 19-2 and 19-3). The heart should fill less than one third of the area of the thorax,⁷³ and the heart's circumference should be less than half the thoracic circumference. These quantitative measurements, like most such measurements in fetal echocardiography, should be considered optional unless an abnormality is suspected, normalcy is in doubt, or measurements are desired for incorporation into a database.

The fetal heart's right-sided structures should be equal to or, more commonly, slightly larger than their respective left-sided structures.⁷⁴ Mild right heart disproportion appears to occur in some cases of trisomy 21, even in the absence of structural disease.¹⁰⁵ With advancing gestation, the right side of the heart becomes progressively more dominant, making the diagnosis of right heart disproportion much more common during the third trimester than during the second.⁷⁴ For this

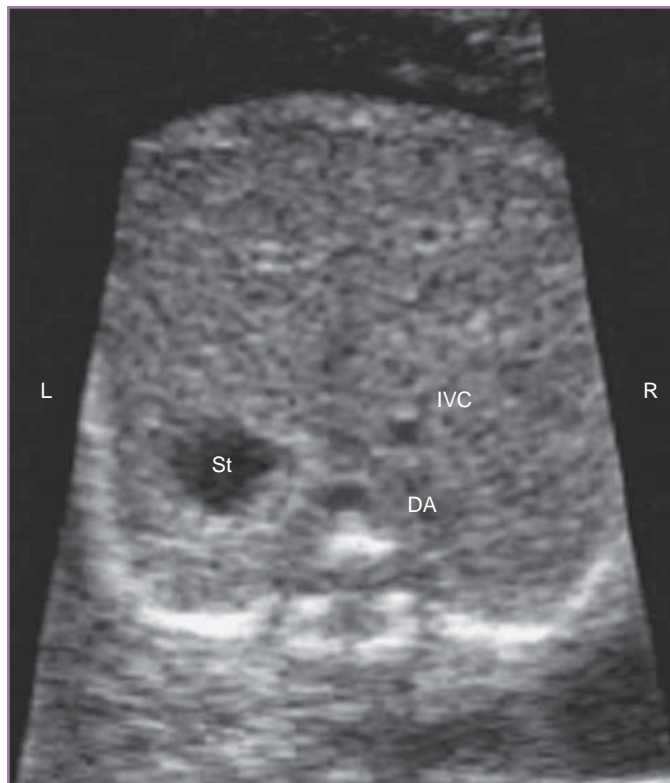


FIGURE 19-10 Fetal echocardiographic image of abdominal situs view. Compare with Figure 19-9. DA, descending aorta; IVC, inferior vena cava; L, fetal left; R, fetal right; ST, stomach.

reason, false-positive diagnoses of coarctation of the aorta occur most frequently late in gestation.

Venous Drainage

Although evaluation of systemic and pulmonary venous drainage may be accomplished with 2D imaging alone, color flow imaging helps to confirm the anatomy and to demonstrate areas of obstruction,¹⁰⁶ and spectral Doppler may help to assess cardiovascular status still further.^{86,90,91,103} With slight inferior angulation or tilting of the transducer from the 4CV, the coronary sinus should be seen coursing from left to right just above the mitral groove (Fig. 19-11). At the level of the 4CV, the coronary sinus sometimes may be seen in cross section laterally, adjacent to the left atrial free wall just above the mitral annulus. However, enlargement of the coronary sinus should prompt evaluation for either a left-sided superior vena cava (LSVC)^{107,108} or drainage of some or all pulmonary veins directly into the coronary sinus. All four pulmonary veins may be seen, but such visualization can be time-consuming and challenging; therefore, visualization by color flow Doppler of even one or two pulmonary veins (Figs. 19-12 and 19-13; see Fig. 19-3) draining normally to the left atrium is generally sufficient^{1,85} in the absence of suspected disease. The presence of a ridge of tissue (normal pericardial reflection, or infolding of tissue between the left atrial appendage and left pulmonary vein) extending a short distance medially from the posterior/lateral aspect of the left atrium helps to rule out total anomalous pulmonary venous return. Color flow imaging should be performed to confirm normal, unobstructed pulmonary venous return to the left atrium. Spectral Doppler analysis may be performed if color Doppler suggests pathol-

FIGURE 19-11 Schematic diagrams of coronary sinus views. **A**, Longitudinal coronary sinus view obtained with slight inferior angulation from the four-chamber view. The coronary sinus (*arrow*) drains along the mitral annulus before opening into the right atrium and can be seen in normal fetuses. **B**, Four-chamber view demonstrating dilated coronary sinus in cross section (*arrow*) at the lateral aspect of the mitral annulus. A normal coronary sinus is usually small or not seen at all with this perspective. LA, left atrium; LV, left ventricle; RA, right atrium; RV, right ventricle. (Diagrams courtesy of Irving R. Tessler, M.D.)

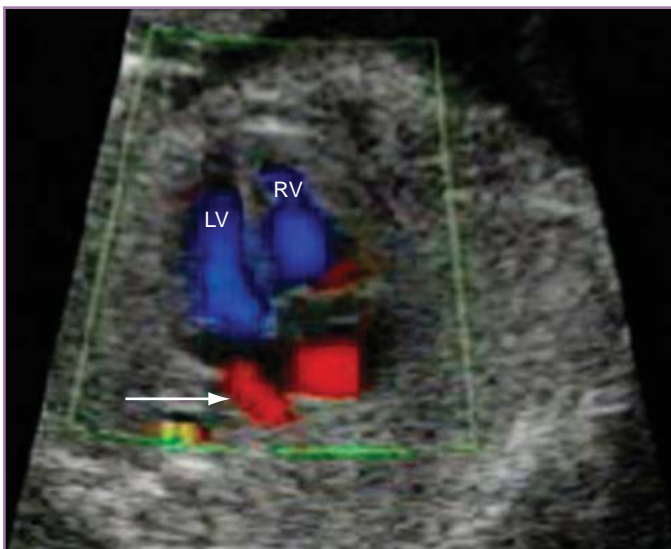
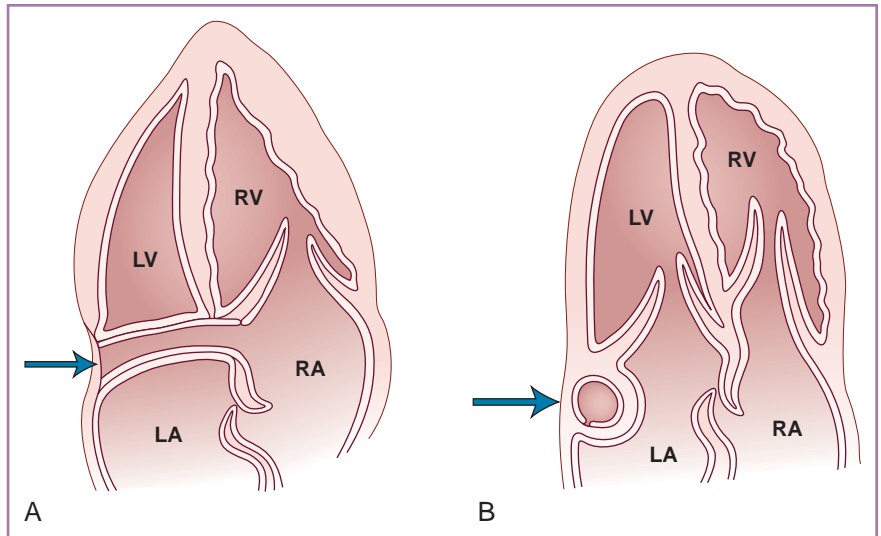


FIGURE 19-12 Fetal echocardiographic image of four-chamber view. Color flow imaging demonstrates a right-sided pulmonary vein (*arrow*) draining into the left atrium. LV, left ventricle; RV, right ventricle.

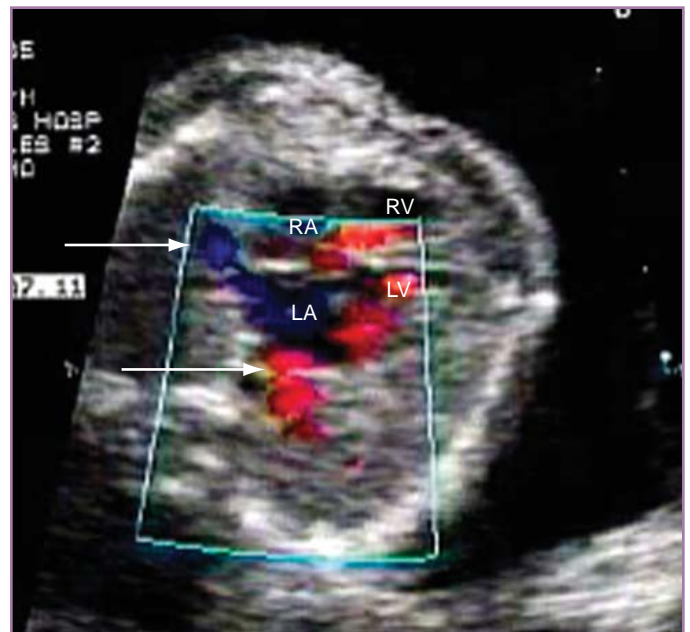


FIGURE 19-13 Fetal echocardiographic image of four-chamber view. Color flow imaging demonstrates right and left pulmonary veins (*arrows*) draining into the left atrium. LA, left atrium; LV, left ventricle; RA, right atrium; RV, right ventricle.

ogy.⁹¹ Structural abnormalities of venous return raise the possibility of heterotaxy.^{106,109,110}

Atrial Septum

Because the foramen ovale normally shunts oxygenated blood from the right atrium to the left atrium, the flap of the foramen ovale should be deviated toward the left atrium. Although this flap typically moves back and forth during the cardiac cycle, the dominant position should be leftward (see Fig. 19-2). The flap itself should occupy a central position within the atrial septum, and it should extend increasingly further into the left atrium with advancing gestational age. Both the superior and inferior aspects of the atrial septum should appear intact, although the superior rim may not always be seen with routine screening. Occasionally, particularly when dilated, the coronary sinus (seen longitudinally) may generate the appearance of an absent inferior portion of

the atrial septum (Fig. 19-14).¹⁰⁷ For this reason, if this portion of the atrial septum appears deficient, care must be taken to confirm that the image plane has not simply been directed too far posteriorly/inferiorly from the 4CV.

Atrioventricular Valves

The atrioventricular valve morphology and function should be evaluated, along with the rest of the heart, during real-time motion. Both valves may be evaluated in their entirety from the 4CV (see Figs. 19-2 and 19-3), although visualization from other views may be useful, particularly if abnormalities are present or suspected. The tricuspid valve annulus should be the same size or slightly larger than the mitral

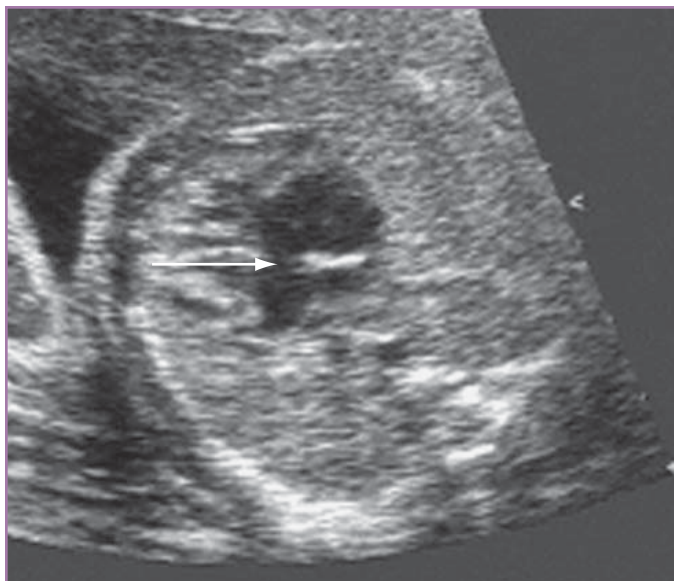


FIGURE 19-14 Fetal echocardiographic image of dilated coronary sinus, obtained with slight inferior angulation from the four-chamber view. The dilated coronary sinus orifice (*arrow*) mimics ostium primum atrial septal defect.

annulus. The leaflets should appear thin and delicate, with unrestricted diastolic excursion into their respective ventricles. A subtle abnormality of either valve early in the second trimester may progress to a severe abnormality, or even to hypoplastic right or left heart syndrome, at term. The septal leaflet of the tricuspid valve should insert slightly more apically onto the ventricular septum than the septal leaflet of the mitral valve does. The papillary muscles of the tricuspid valve should have attachments to the ventricular septum and right ventricular free wall. In contrast, the papillary muscles of the mitral valve should have no attachments to the ventricular septum. Evaluation of the atrioventricular valves should always include color flow imaging to assess for diastolic turbulence or valvar regurgitation. A trace amount of early systolic tricuspid regurgitation probably is normal,¹¹¹ although many investigators consider any tricuspid regurgitation prenatally to be abnormal.¹¹² Prenatal valvar regurgitation of any other valve is generally considered abnormal. Fetuses with trisomy appear to have an increased incidence of tricuspid regurgitation, even in the presence of a structurally normal heart.¹⁰⁵ Measurement of tricuspid and mitral valve annulus size,^{95-97,99,100} as well as spectral Doppler evaluation of inflow patterns,⁹²⁻⁹⁴ should be performed if an abnormality is suspected, if normalcy cannot be confirmed, or if additions to a database are desired.

Ventricles

The structure and function of both ventricles should be evaluated in detail. The 4CV provides the single best perspective to evaluate ventricular structure (see Figs. 19-2 and 19-3). Both ventricles should extend to the cardiac apex, and both should squeeze symmetrically during systole. The left ventricle should be smooth walled, aligned with the mitral valve, and located leftward and posterior to the right ventricle. The right ventricle should be more heavily trabeculated, should have a moderator band of tissue crossing the ventricle near the apex, should be aligned with the tricuspid valve, and should be located rightward and anterior to the left ventricle. The right ventricle should be equal in size or, more commonly, slightly larger than the left ven-

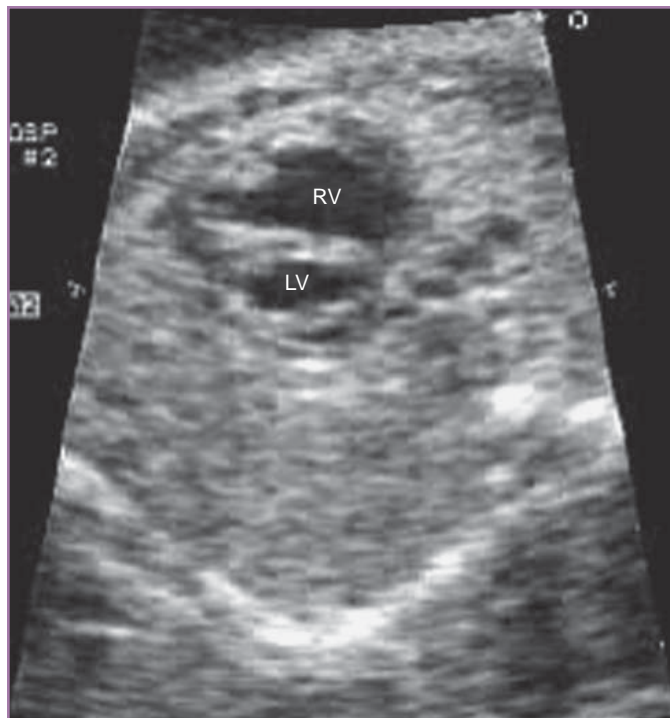


FIGURE 19-15 Fetal echocardiographic image of apical short-axis view. Right ventricular disproportion is demonstrated. LV, left ventricle; RV, right ventricle.

tricle, with right heart predominance increasing normally with advancing gestational age. Mild right heart disproportion (Fig. 19-15) has been associated with trisomy 21.¹⁰⁵ Quantitative assessment of ventricular systolic and diastolic function^{86-89,92-94,102,113} may be performed if an abnormality is suspected, if normalcy cannot be confirmed, or if additions to a database are desired. However, close attention to ventricular systolic function should always be made qualitatively and from multiple views, including the 4CV and basal short-axis view (obtained from a sagittal fetal orientation). Ventricular dysfunction may be isolated and primary,¹¹⁴ or it may be associated with structural heart disease.

The presence of small, circumscribed echogenic densities, foci, or reflectors within the chordal apparatus of the mitral valve (or, less commonly, tricuspid valve) should probably be considered, from a cardiovascular standpoint, as benign variants of normal.¹¹⁵⁻¹¹⁷ If doubt exists regarding the diagnosis, further evaluation should be performed to rule out CHD. Although the data remain somewhat controversial, such echogenic foci do appear to be more prevalent among fetuses with aneuploidy than among those with normal chromosomes.¹¹⁶⁻¹¹⁹

Ventricular Septum

The ventricular septum should be evaluated for thickness, motion, and the presence of a VSD. The ventricular septum should be roughly the same thickness as the left ventricular posterior free wall, and it should contract symmetrically with the left ventricular free wall. Ventricular septal thickness may be evaluated from the 4CV and the basal short-axis view. In cases of suspected septal hypertrophy, the septal thickness should be measured, typically during both diastole and systole. The entirety of the ventricular septum then needs to be evaluated for VSDs. 2D imaging should be performed from multiple views and with multiple sweeps, seeking to identify any defect in any portion of the ven-

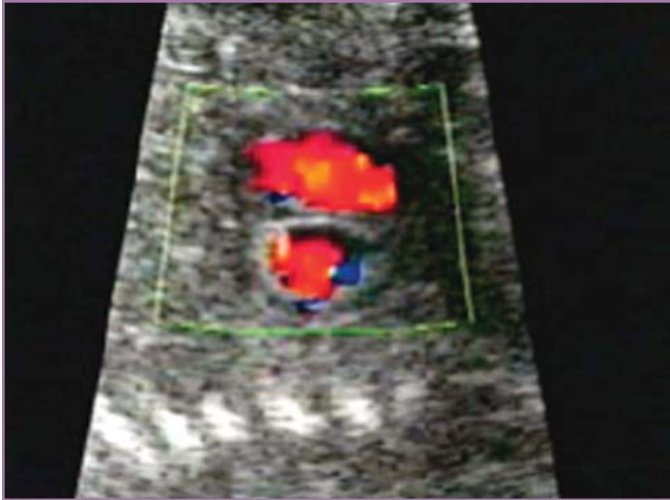


FIGURE 19-16 Fetal echocardiographic image of apical short-axis view. Color flow imaging demonstrates intact muscular ventricular septum.

tricular septum. To avoid false-positive “drop out” in the inlet and membranous portions of the ventricular septum, 2D imaging should be performed as perpendicular as possible to the ventricular septum and with the transducer angled slowly from the 4CV into the left ventricular long-axis view (see Figs. 19-4 and 19-5). Color flow imaging should also always be performed in search of VSDs (Fig. 19-16), using the same perpendicular orientations and sweeps; some defects may not be visualized with 2D imaging alone.

Outflow Tracts in Motion

Semilunar Valves

The semilunar (aortic and pulmonary) valves should be evaluated with the same attention to anatomy and function that is given to the evaluation of the atrioventricular valves. Consistent with the right-sided predominance seen at the levels of the atrium, atrioventricular valve, and ventricle, the pulmonary valve annulus should be equal in size or, more commonly, slightly larger than the aortic valve annulus. The aortic valve may be best visualized with a left ventricular long-axis view (see Fig. 19-5), which is obtained with slight anterior/superior angulation from the 4CV. In addition, ideally, the probe may be rotated slightly from a transverse cut toward a partially sagittal plane. The aortic valve may be evaluated further with a basal short-axis view, which is obtained from a sagittal fetal orientation. The pulmonary valve (RVOT crossing view) (see Fig. 19-7) may be evaluated with slight anterior/superior angulation from the left ventricular long-axis view. In addition, the pulmonary valve may be evaluated further with a basal short-axis view. The aortic valve should arise from the anterior aspect of the left ventricle, and the pulmonary valve from the anterior aspect of the right ventricle. Both aortic and pulmonary valves should be thin and delicate, with unrestricted excursion during systole, resulting in the valve’s practically disappearing from view when fully open (see Fig. 19-5). During diastole, the aortic and pulmonary valves should appear as central points or symmetrical, thin plates. The aortic valve, during diastole, should appear on the left ventricular long-axis view as a thin, central plate, parallel to the axis of the aortic root. The pulmonary valve during diastole, in contrast, should appear on the basal short-axis view also as a thin plate but perpendicular to the axis of the main

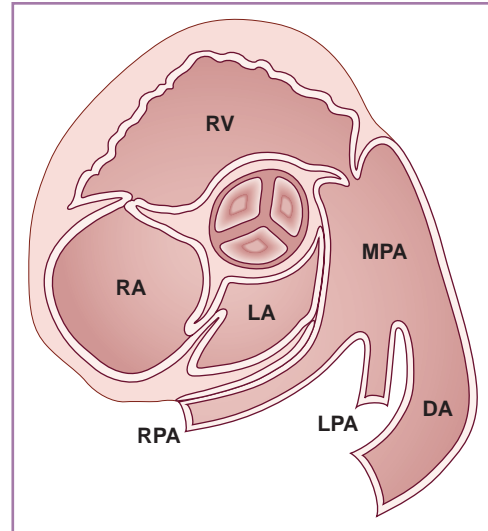


FIGURE 19-17 Schematic diagram of fetal basal short-axis/ductal arch view. The left pulmonary artery and ductus arteriosus commonly appear superimposed in this view. DA, ductus arteriosus; LA, left atrium; LPA, left pulmonary artery; MPA, main pulmonary artery; RA, right atrium; RPA, right pulmonary artery; RV, right ventricle. (Diagram courtesy of Irving R. Tessler, M.D.)

pulmonary artery. A subtle abnormality of either valve during the early second trimester may progress to a severe valve abnormality, or even to hypoplastic left or right heart syndrome, at term. Measurement of aortic or pulmonary valve annulus size, or evaluation of the systolic Doppler flow profile, or both, should be performed if an abnormality is suspected, if normalcy cannot be confirmed, or if additions to a database are desired. However, evaluation of aortic and pulmonary valves should always include color flow imaging to assess for aortic or pulmonary regurgitation (always abnormal) or systolic turbulence suggestive of increased flow volume or anatomic obstruction.

Great Arteries and Ductal and Aortic Arches

The ascending aorta (aortic root) and main pulmonary artery should arise from the left and right ventricles, respectively, and then cross at an angle of roughly 45 to 90 degrees. Demonstration of great artery crossing represents an important finding on the normal fetal echocardiogram. This crossing can be seen either with transverse imaging (slight anterior/superior angulation from the 4CV to left ventricular long-axis view to RVOT crossing view) or with sagittal imaging (slight leftward angulation from sagittal aortic arch view to ductal arch view). In general, the aortic root should point to the right of the spine (see Fig. 19-5), and the main pulmonary artery should point to the left of the spine (see Fig. 19-7). As with other right-left ratios in the fetal heart, the main pulmonary artery should be equal in size or, more commonly, slightly larger than the aortic root. The ductal arch and basal short-axis views (Figs. 19-17, 19-18, and 19-19) should demonstrate the trifurcation of the main pulmonary artery into the right pulmonary artery (which wraps around the aorta in the basal short-axis view), the left pulmonary artery, and the ductus arteriosus (the largest of the three branches).

In cases of suspected pathology, the branch pulmonary arteries should be measured and their Doppler flow profiles obtained. For instance, fetal pulmonary artery diameter may correlate with outcome in cases of congenital diaphragmatic hernia.¹²⁰ In cases of suspected ductal constriction (i.e., tricuspid and pulmonary regurgitation across

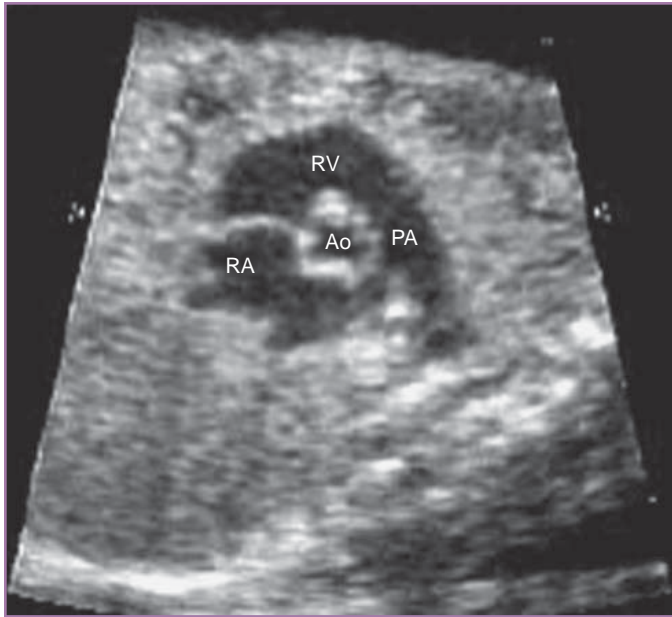


FIGURE 19-18 Fetal echocardiographic image of basal short-axis view during systole. The pulmonary artery bifurcates into the right and left pulmonary arteries. The ductus arteriosus appears superimposed over the left pulmonary artery. The pulmonary valve is open and is closely opposed to the main pulmonary artery. Ao, aorta; PA, main pulmonary artery; RA, right atrium; RV, right ventricle.

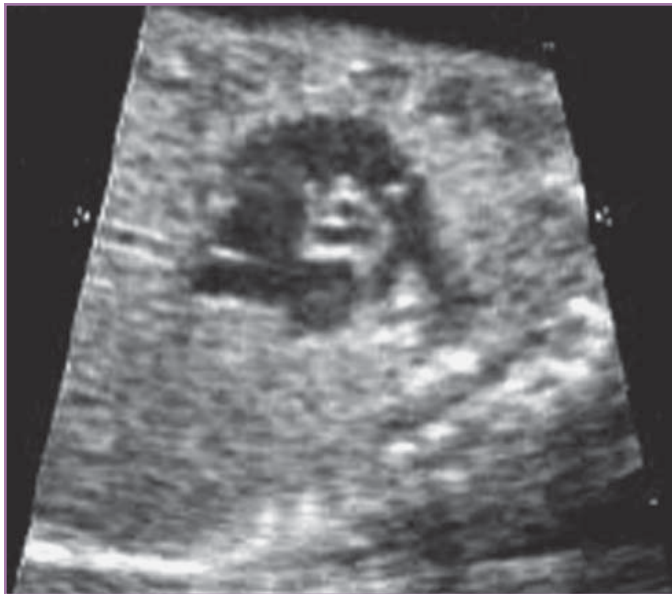

FIGURE 19-19 Fetal echocardiographic image of basal short-axis view during diastole. The aortic and pulmonary valves appear in their closed positions, and the tricuspid valve is open.

normal-appearing valves, or simply fetal exposure to indomethacin¹²¹), the flow profile of the ductus arteriosus should be obtained parallel to flow on the sagittal ductal arch view. A pulsatility index of less than 1.9 suggests ductal constriction,¹²¹ whereas a pulsatility index greater than 3 suggests increased right ventricular output and left heart obstruction.¹²² The sagittal aortic arch view (Figs. 19-20 and 19-21), obtained with rightward angulation from the ductal arch view, dem-

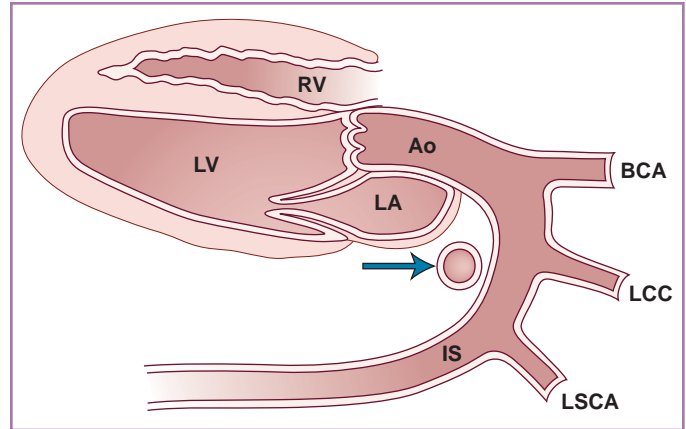


FIGURE 19-20 Schematic diagram of fetal sagittal aortic arch view. The aortic arch crosses over the right pulmonary artery (arrow). Ao, aortic arch; BCA, brachiocephalic artery; IS, aortic isthmus; LA, left atrium; LCC, left common carotid artery; LSCA, left subclavian artery; LV, left ventricle; RV, right ventricle. (Diagram courtesy of Irving R. Tessler, M.D.)

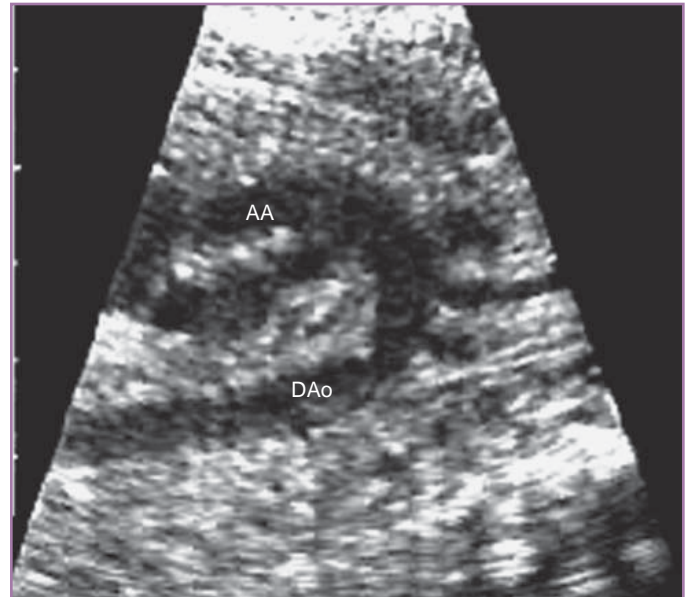


FIGURE 19-21 Fetal echocardiographic image of sagittal aortic arch view. Compare with Figure 19-20. AA, ascending aorta; DAo, descending aorta.

onstrates the aortic arch in its entirety, including aortic root, transverse aortic arch, aortic isthmus, and descending aorta. Color flow imaging should always be performed of the entire aortic (Fig. 19-22) and ductal arches. Measurements of aortic dimensions^{95,96,98} should be obtained if an abnormality is suspected, if normalcy cannot be confirmed, or if additions to a database are desired.

Evaluation for Fetal Congestive Heart Failure

Fetal CHF may be related to extracardiac disease (e.g., anemia, cerebral arteriovenous fistula, twin-twin transfusion syndrome) or to fetal

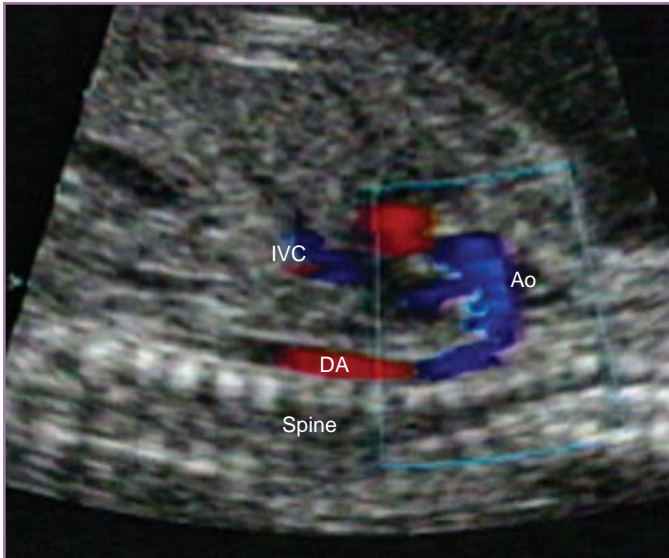


FIGURE 19-22 Fetal echocardiographic image of sagittal aortic arch view. Color flow imaging demonstrates prograde flow into aortic arch (Ao) and descending aorta (DA). IVC, inferior vena cava.

TABLE 19-4 CAUSES OF FETAL CONGESTIVE HEART FAILURE

Anemia
Twin-twin transfusion syndrome
Arteriovenous malformation
Diaphragmatic hernia
Pericardial effusion
Cardiac Causes
Hypertrophic cardiomyopathy
Dilated cardiomyopathy
Sustained bradycardia/tachycardia
Valvar regurgitation
Restrictive foramen ovale
Ductal constriction

heart disease (Table 19-4). Some of the most severe forms of CHD (e.g., hypoplastic left heart syndrome [HLHS], TOF with pulmonary atresia and ductal-dependent pulmonary blood flow) do not typically generate fetal CHF. Rather, fetal heart disease that causes CHF almost invariably includes one or more of the following^{103,123,124}: sustained tachycardia or bradycardia (i.e., supraventricular tachycardia [SVT] or complete heart block), myocardial dysfunction (i.e., dilated cardiomyopathy), valvar regurgitation (i.e., Ebstein anomaly of the tricuspid valve or TOF with absent pulmonary valve), or restrictive flow across the foramen ovale or ductus arteriosus.¹²² The fetus with absence of a valve (e.g., tricuspid atresia) or absence of a ventricle (e.g., HLHS) generally does better prenatally than one with a poorly functioning valve or ventricle.

Unlike the postnatal diagnosis of CHF, which relies more on clinical signs (tachycardia, tachypnea, hepatomegaly, rales, and peripheral edema) than on radiographic or echocardiographic findings, the prenatal diagnosis of CHF relies exclusively on sonographic findings.^{86,103,123,124} The sonographic findings associated with fetal CHF from any cause include (1) dilated, poorly squeezing ventricle with systolic and diastolic dysfunction; (2) cardiomegaly; (3) pericardial

TABLE 19-5 SONOGRAPHIC FINDINGS IN FETAL CONGESTIVE HEART FAILURE

Cardiomegaly
Tricuspid regurgitation
Pericardial effusion
Diminished ventricular systolic function
Increased atrial flow reversal in systemic veins

effusion; (4) tricuspid regurgitation; and (5) increased atrial flow reversal in the systemic veins (Table 19-5). More detailed cardiac and peripheral Doppler evaluation also may be performed.^{86,103,124,125} Severe forms of CHF lead to hydrops and cardiac pulsations within the free-floating umbilical vein. The diagnosis of fetal CHF or hydrops should prompt further evaluation for clues to the etiology, as well as serial follow-up studies, given the potential for progression of disease and even fetal demise.

Three-dimensional Fetal Cardiac Imaging

Background

At the current time, 3D fetal cardiac imaging^{60-62,64,77,126-149} remains predominantly an investigational tool for academic centers seeking to improve and enhance the prenatal detection and diagnosis of CHD. Because of persistent challenges related to image resolution, substantial learning curves, and expensive equipment, 3D fetal cardiac imaging has not yet become an acceptable alternative to conventional 2D imaging.

That said, compared with 2D fetal cardiac imaging, 3D imaging carries important advantages that promise to revolutionize the clinical approach to fetal cardiac imaging.^{60,63,131,140} First, 3D imaging, by acquiring a comprehensive volume dataset within a matter of a few seconds, makes fetal cardiac imaging less operator dependent and less time-consuming to perform. Second, 3D volume datasets may be evaluated interactively offline, enabling virtual examinations of the entire fetal heart, with reconstruction of any plane or sweep, after the initial, short acquisition. Such interactive evaluations may be performed at the bedside, remotely by centers with expertise,⁷⁶ or even, potentially, automatically using evolving algorithms designed to automate the process of screening for CHD.^{63,75} Third, volume-rendering algorithms display data as “surgeon’s-eye views,” enabling visualization of the internal architecture and anatomy of the fetal heart (Figs. 19-23 and 19-24) or great arteries from any perspective. Such displays improve comprehension of complex forms of CHD, leading to improved patient counseling and patient selection for fetal interventions. Moreover, evolving technology allows the 3D visualization of color-flow jets within volume-rendered displays or as stand-alone “angiograms.”^{135,138} Finally, 3D volume datasets enable more accurate quantitative measurements of ventricular size and function,^{139,141} which can translate into improved ability to predict the prenatal and postnatal courses of CHD from early in the second trimester (or even earlier).

Technique

Three-dimensional fetal cardiac imaging may be performed with either a reconstructive^{61,62,126-130,142-144} or a real-time^{60,132,133,136,137,139,145,146} approach. Reconstructive approaches use specialized probes to image

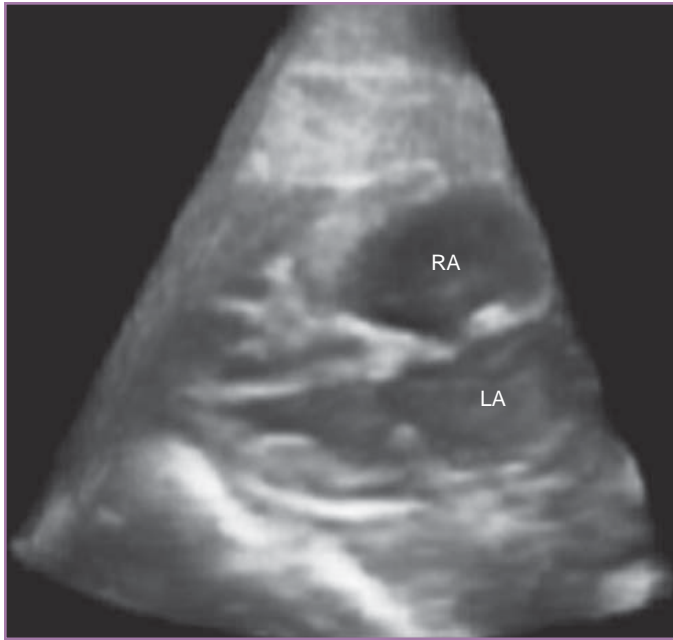


FIGURE 19-23 Fetal echocardiographic real-time three-dimensional rendered image of normal four-chamber view. LA, left atrium. RA, right atrium.

the fetal heart as an automated sweep, acquiring a series of parallel planar images over 7 to 15 seconds. The images and their spatial coordinates are subsequently reconstructed into a volume dataset or, using gating algorithms to view cardiac motion,^{126,129,142,147} into a series of volume datasets for subsequent display and review. Reconstructive approaches have a disadvantage in that they require the fetus and mother to be relatively motionless throughout the acquisition; any fetal or maternal motion distorts the reconstructed volume dataset.

In contrast, real-time approaches use specialized probes to image the fetal heart as a volume, acquiring the entire fetal heart (or portion thereof) virtually instantaneously. The volume data do not require reconstruction, and they do not require gating algorithms (as do reconstructive techniques) to view cardiac motion. Real-time approaches make the most sense for imaging the fetal heart, given their quick acquisition time (2 seconds), relative resistance to artifact derived from random fetal motion, and lack of a need for cardiac gating.^{60,132,136,137,145,146} However, real-time approaches are unable to acquire large volumes in real time, and they have relatively poor image resolution compared with reconstructive approaches.

After volume data have been acquired, via either reconstructive or real-time techniques, volume datasets may be reviewed interactively, displaying any plane,^{62,128} rendered volume,^{60,62,143,144} or sweep of interest and allowing precise quantitative measurements of ventricular size and function.¹⁴⁷⁻¹⁴⁹ Investigators continue to develop new ways to display volume data,^{77,138,144} in an effort maximally to exploit the potential clinical utility of 3D sonographic data (Figs. 19-25 and 19-26).

The Future

Within the next 10 years, 3D imaging (most likely real-time rather than reconstructive imaging) may become the standard of care, both for prenatal screening for CHD and for detailed evaluation of complex CHD using rendered displays, color flow imaging, and quantitative measurements. Ultimately, 3D imaging may automate the display of

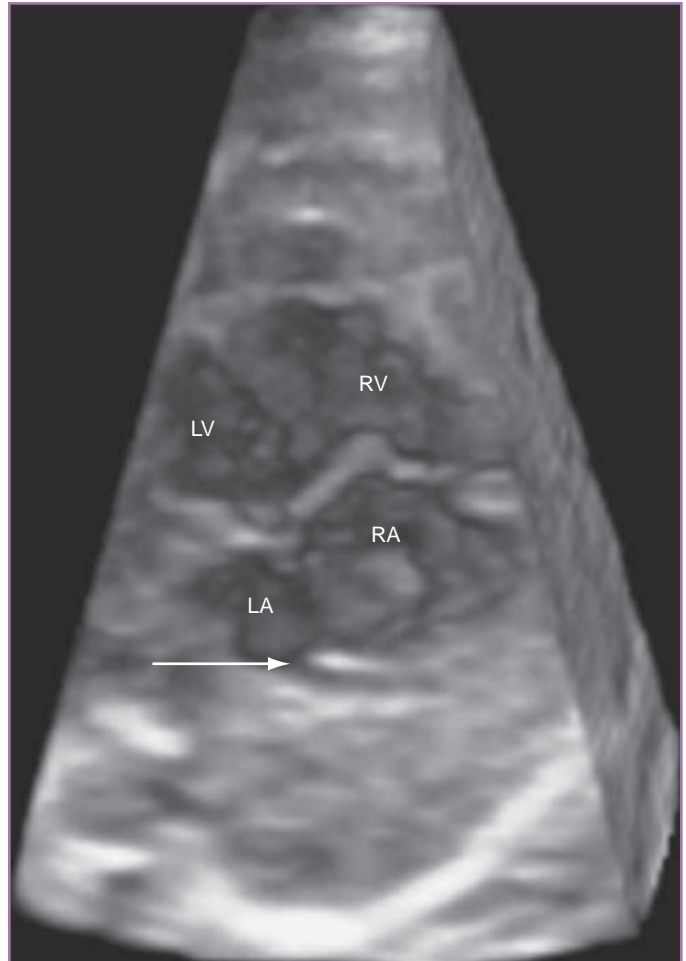


FIGURE 19-24 Fetal echocardiographic real-time three-dimensional rendered image of mitral atresia with hypoplastic left ventricle. Arrow points to right-sided pulmonary vein draining to left atrium. LA, left atrium; LV, left ventricle; RA, right atrium; RV, right ventricle.

important planes and sweeps, representing a novel form of computer-aided prenatal detection and diagnosis of CHD.^{63,75}

Fetal Cardiac Malformations: Diagnosis, Management, and Prognosis

This section aims to help the obstetrician, perinatologist, radiologist, cardiologist, and sonographer to recognize and diagnose the most common and important forms of fetal cardiac malformations (Table 19-6) and to understand their management and prognosis. The embryology of certain defects is described briefly; more detailed descriptions may be found elsewhere.^{8,9,150-153} Likewise, more thorough descriptions of individual defects, as well as lesion-specific management and prognosis, may be found elsewhere in standard texts.^{8,9,152,153}

Readers should keep in mind that any single heart defect may occur in conjunction with other cardiac defects; often, the most difficult fetal cardiac defect to detect is the second one. Because of the

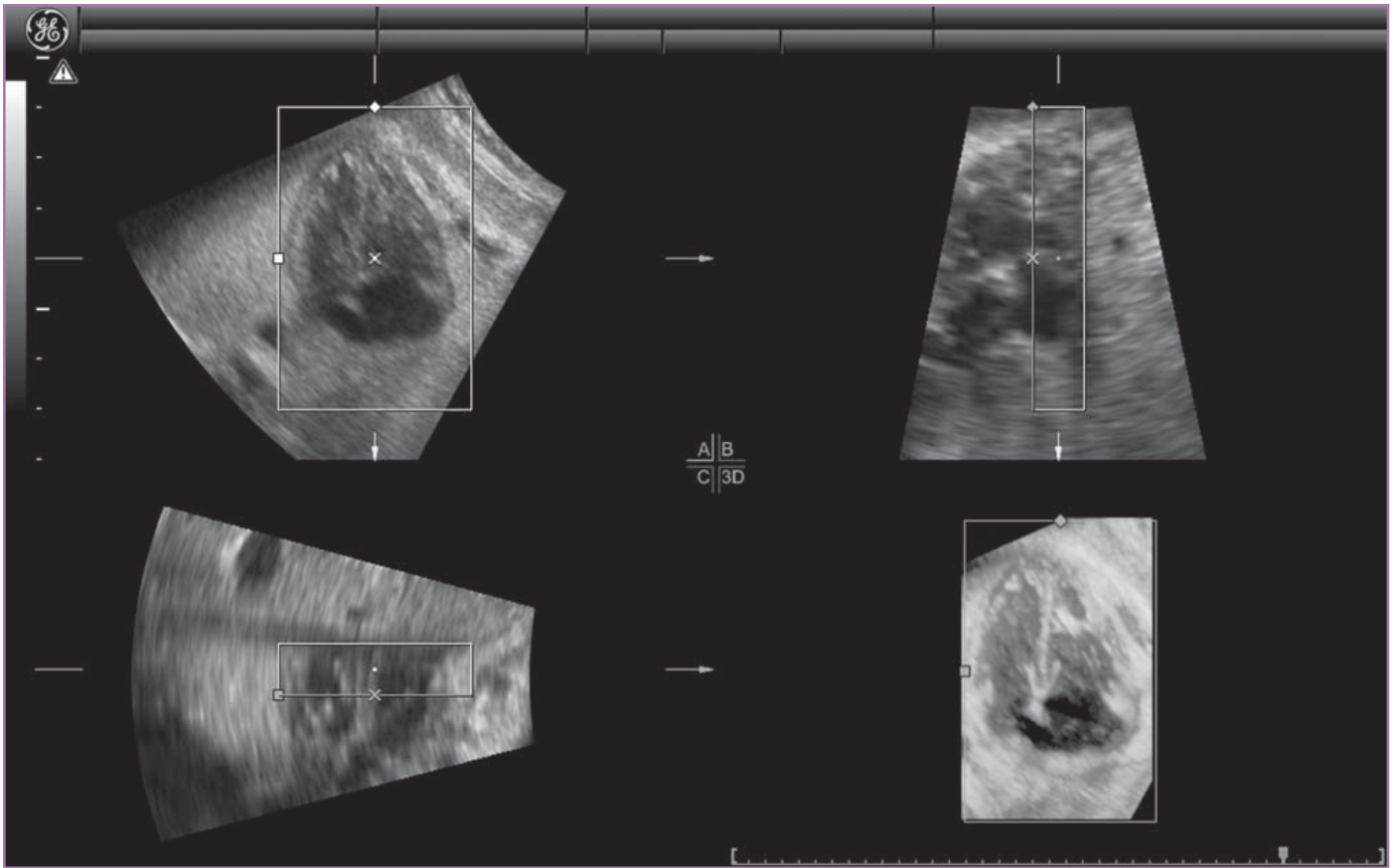


FIGURE 19-25 Fetal echocardiographic reconstructive three-dimensional multiplanar display. Normal fetal cardiac anatomy is demonstrated from three orthogonal planes and in a rendered image at lower right. (Image courtesy of Gregory R. DeVore, M.D.)

complexity of various forms of fetal structural heart defects, as well as their common association with maternal or extracardiac fetal disease, a multidisciplinary team (potentially including an obstetrician, perinatologist, radiologist, pediatric cardiologist, neonatologist, social worker, genetics counselor, nurse, and cardiothoracic surgeon) should jointly manage pregnancies complicated by complex fetal heart disease.

Systemic Venous Anomalies

Persistent Umbilical Vein

Normally, during embryonic development, bilateral umbilical veins course along each side of the fetal liver, carrying oxygenated blood from the placenta to the fetal heart. The right umbilical vein involutes, along with the left umbilical vein's connection to the heart. The persistent portion of the left umbilical vein becomes the fetal umbilical vein, which carries oxygenated blood to the IVC via the ductus venosus. Rarely, the right umbilical vein fails to involute. In such cases, the fetus may be found to have a large, unobstructed vein connecting from the cordal insertion site directly to the right atrium (Fig. 19-27). A persistent right umbilical vein may be associated with structural cardiac defects, right heart disproportion, extracardiac defects, or aneuploidy, or it may simply be an isolated anomaly, usually well tolerated but occasionally associated with CHF.¹⁵⁴⁻¹⁵⁶ Commonly, a persistent right umbilical vein is associated with absence of the ductus venosus.

The finding of a persistent right umbilical vein should prompt a detailed evaluation for other structural defects, cardiac and extracar-

diac, as well as cardiac function.¹⁵⁴⁻¹⁵⁶ Patients also should be advised of the potential for aneuploidy. All cases deserve neonatal clinical and echocardiographic follow-up, although, if the anomaly is isolated, the infant typically does well as the persistent umbilical vein involutes after occlusion of the cord at delivery.

Persistent Left-sided Superior Vena Cava

Normally, during embryogenesis, the right-sided superior vena cava forms from the right anterior cardinal vein and the right common cardinal vein. Abnormal persistence of the left anterior cardinal vein, which normally involutes during embryogenesis, leads to the presence of a persistent LSVC in the fetus and newborn. A persistent LSVC typically drains through the coronary sinus and into the right atrium (Fig. 19-28; see Figs. 19-11 and 19-14). In such cases, a right-sided superior vena cava (normal) may or may not be present (Fig. 19-29).

Cases of persistent LSVC may be detected in the fetus by visualization of an enlarged coronary sinus (see Fig. 19-11) in the 4CV^{106,107} or by direct visualization of the LSVC (see Fig. 19-28). The finding of a persistent LSVC may be isolated, resulting in physiological return of deoxygenated blood to the right atrium, albeit via an abnormal pathway. Such cases represent variations of normal and do not require any intervention, either prenatally or after birth. However, persistent LSVC may be associated with left-sided obstructive lesions (e.g., coarctation of the aorta, valvar aortic stenosis, HLHS),¹⁰⁸ so the finding should prompt a detailed fetal echocardiographic evaluation and, probably, neonatal echocardiographic follow-up. In some cases,

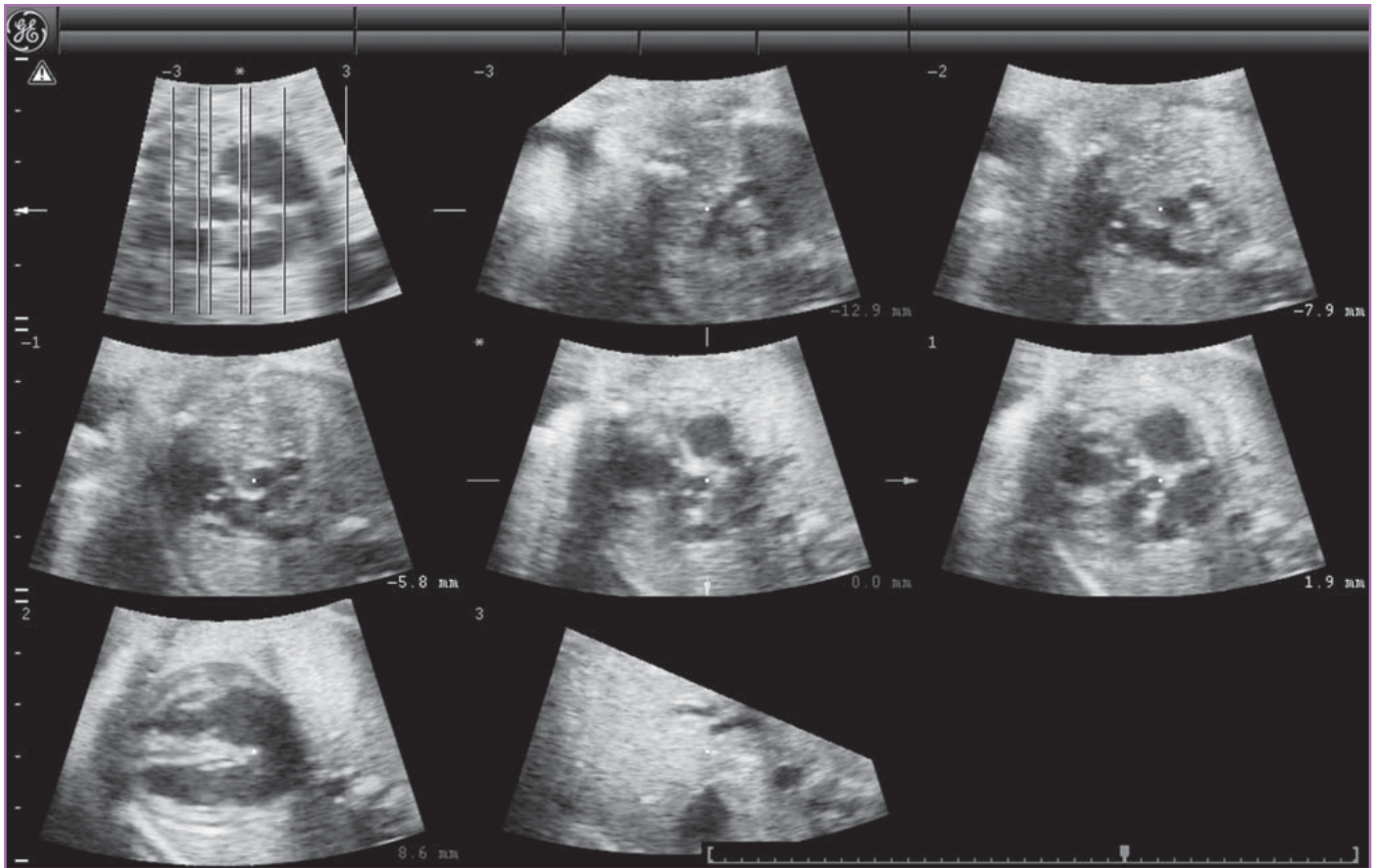


FIGURE 19-26 Fetal echocardiographic reconstructive three-dimensional tomographic ultrasonic image display. Normal fetal cardiac anatomy is demonstrated from multiple parallel planes. (Image courtesy of Gregory R. DeVore, M.D.)

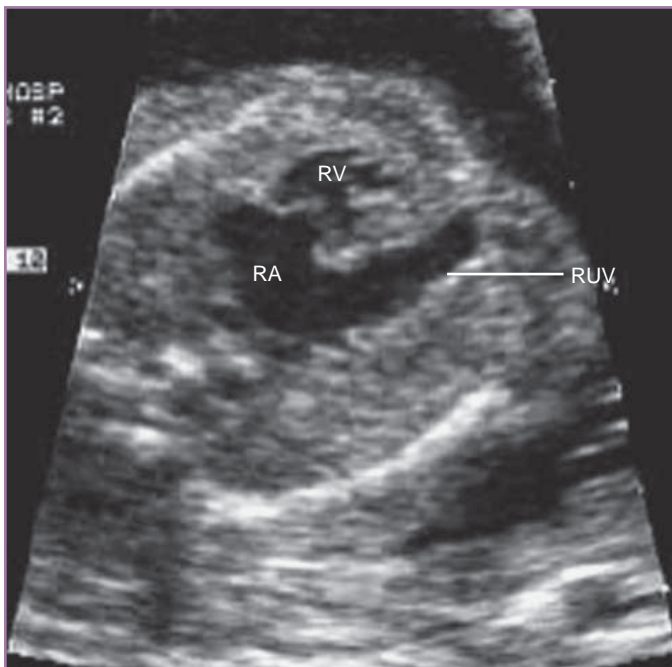

FIGURE 19-27 Fetal echocardiographic image of persistent right umbilical vein. The persistent right umbilical vein (RUV) is shown draining to the right atrium (RA). RV, right ventricle.

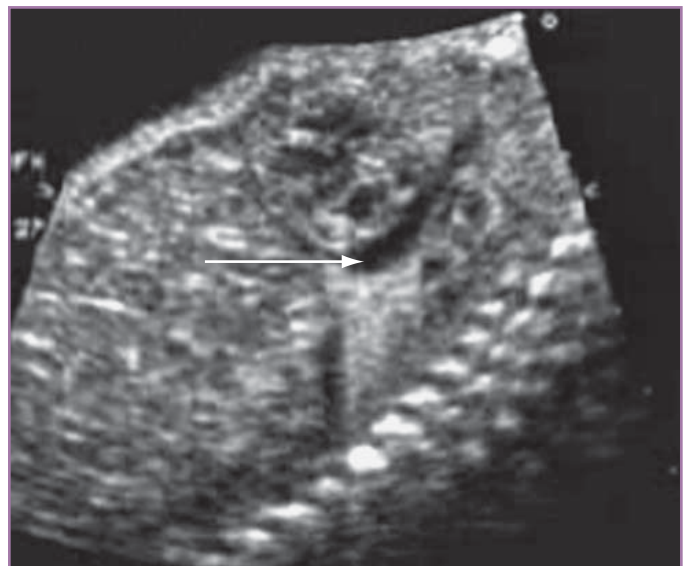


FIGURE 19-28 Fetal echocardiographic sagittal image of left-sided superior vena cava. The persistent left-sided superior vena cava (arrow) is shown draining into the coronary sinus.

TABLE 19-6 FETAL CARDIAC MALFORMATIONS**Systemic Venous Abnormalities**

Persistent umbilical vein
 Interrupted inferior vena cava
 Persistent left-sided superior vena cava

Pulmonary Venous Abnormalities

Partial anomalous pulmonary venous return
 Total anomalous pulmonary venous return

Shunt Lesions

Atrial septal defect
 Ventricular septal defect

Atrioventricular Canal Defect

Complete
 Partial
 Transitional

Tricuspid Valve Dysplasia and Ebstein Anomaly**Right Heart Obstructive Lesions**

Tricuspid atresia
 Pulmonary atresia with intact ventricular septum

Left Heart Obstructive Lesions

Mitral stenosis/atresia (hypoplastic left heart syndrome)
 Valvar aortic stenosis/atresia
 Coarctation of the aorta

Outflow Tract Abnormalities

Tetralogy of Fallot
 Double-outlet right ventricle
 Transposition of the great arteries
 Truncus arteriosus

Tumors

Rhabdomyoma
 Intrapericardial teratoma

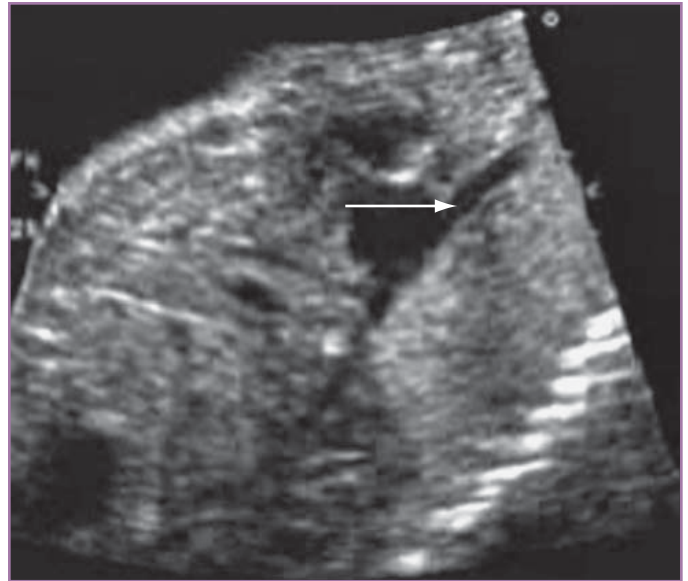


FIGURE 19-29 Fetal echocardiographic sagittal image of right-sided superior vena cava. The normal right-sided superior vena cava (*arrow*) is shown draining into the right atrium. Note inferior vena cava draining into right atrium from below.

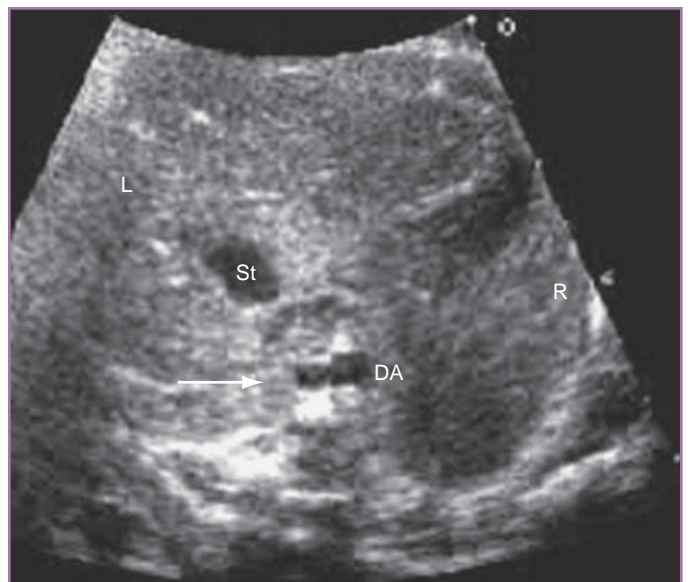


FIGURE 19-30 Ultrasonographic transverse image of fetal abdomen demonstrating an interrupted inferior vena cava with azygos continuation. The azygos vein (*arrow*) appears posterior to the descending aorta (DA), and the intrahepatic inferior vena cava is not visualized. L, fetal left; R, fetal right; St, fetal stomach.

persistent LSVC is associated with extracardiac abnormalities or heterotaxy.^{109,110,157}

Interrupted Inferior Vena Cava

Normally, during embryogenesis, the IVC forms from the right supracardinal vein, subcardinal-supracardinal anastomosis, right subcardinal vein, hepatic vein, and hepatic sinusoids. Occasionally, the hepatic portion of the IVC fails to form, resulting in an interruption of the IVC.¹⁵⁴ In such cases, venous return from the lower half of the fetus drains via a so-called “azygos continuation” of the IVC. The azygos vein returns deoxygenated blood to the right atrium via the superior vena cava.

Interrupted IVC with azygos continuation may be diagnosed prenatally from a transverse view of the abdomen (Fig. 19-30). The cross-sectional image will show, in place of the IVC (within the liver), a cross-sectional image of an azygos vein located posterior to the descending aorta. Sagittal imaging confirms the absence of a direct connection from the IVC to the right atrium; only the hepatic veins are seen to connect directly. Using both 2D and low-velocity color flow sagittal imaging, the azygos vein can be seen longitudinally, located posterior to the aorta and coursing superiorly and anteriorly (Fig. 19-31) to its termination in the superior vena cava.¹⁰⁶

The presence of an IVC with azygos continuation does not, in itself, require any treatment, either prenatally or postnatally. However, this finding should prompt detailed fetal and neonatal echocardiographic evaluations because of the association of interrupted IVC with polysplenia^{110,154,157} with or without structural heart disease. The diagnosis of polysplenia may be further suggested by the presence of a midline liver or fetal bradycardia (absent sinus node). All cases deserve neonatal echocardiographic follow-up.

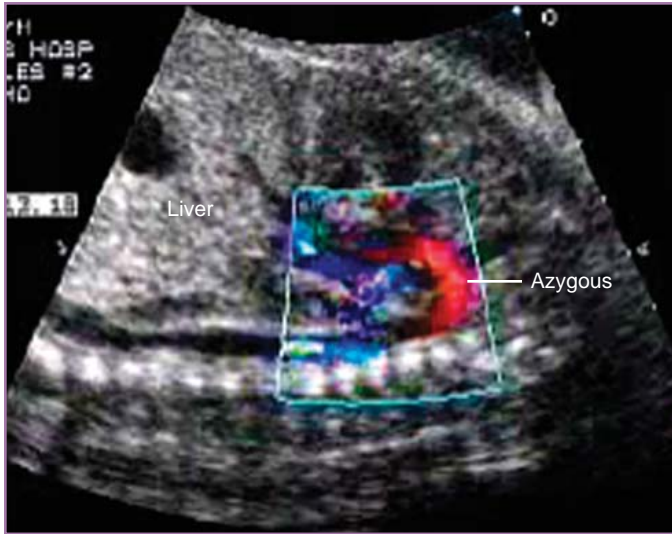

FIGURE 19-31 Fetal echocardiographic sagittal image of azygos vein draining into the superior vena cava. In contrast to retrograde flow into either the aorta or the pulmonary artery (pulsatile), venous flow appears continuous during real-time imaging.

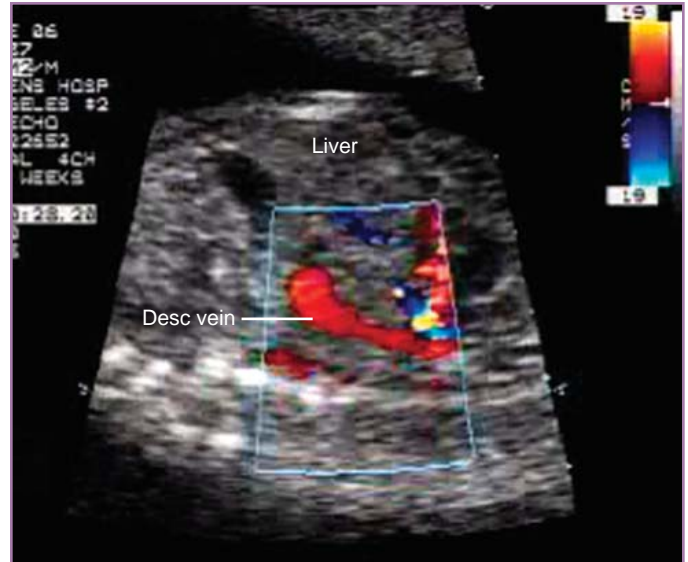

FIGURE 19-32 Fetal echocardiographic sagittal image of infradiaphragmatic total anomalous pulmonary venous return. Color flow imaging demonstrates the descending vein as continuous flow directed inferiorly toward the liver. Desc vein, descending vein.

Pulmonary Venous Abnormalities

Normally, during embryonic development, the common pulmonary vein evolves to form not only four separate pulmonary veins but also much of the left atrium itself. Cases of partial anomalous pulmonary venous return (PAPVR), involving one to three veins, or total anomalous pulmonary venous return (TAPVR), involving all four veins, result from abnormalities of this portion of embryogenesis.¹⁵⁰⁻¹⁵⁴ As with abnormalities of systemic venous return, both 2D and color flow imaging play important roles in the diagnosis of anomalous pulmonary venous return. Color flow imaging can facilitate visualization of normal (see Figs. 19-12 and 19-13) or anomalous (Figs. 19-32 and 19-33) pulmonary venous return when the scale has been adjusted for low-velocity flows. Anomalous pulmonary venous return frequently occurs in association with heterotaxy.^{106,110,157}

Partial Anomalous Pulmonary Venous Return

Because even detailed fetal echocardiography may not routinely demonstrate all four pulmonary veins, many cases of PAPVR may be overlooked prenatally, unless they are associated with other cardiac abnormalities. This section discusses two types of PAPVR that may be detectable before birth because of associated findings. In general, however, PAPVR usually does not require neonatal intervention and carries an excellent long-term prognosis.

Scimitar syndrome represents an unusual form of PAPVR in which the right-sided pulmonary vein (or veins) returns to a vein that descends through the diaphragm before joining the IVC just proximal to the right atrium. Postnatally, this vein may appear radiographically like a sword, or scimitar; hence, the name of the syndrome. In addition, typically, a collateral vessel arising from the descending aorta supplies a separate part of the right lung. Color flow imaging may demonstrate anomalously draining right-sided pulmonary venous return. Further evaluation may demonstrate a collateral vessel arising from the descending aorta and supplying a portion of the right lung. The fetus with scimitar syndrome may have minimal or no right heart disproportion but frequently presents with dextrocardia or mesocardia.¹⁵⁸ Commonly, the syndrome occurs in association with a secundum ASD,

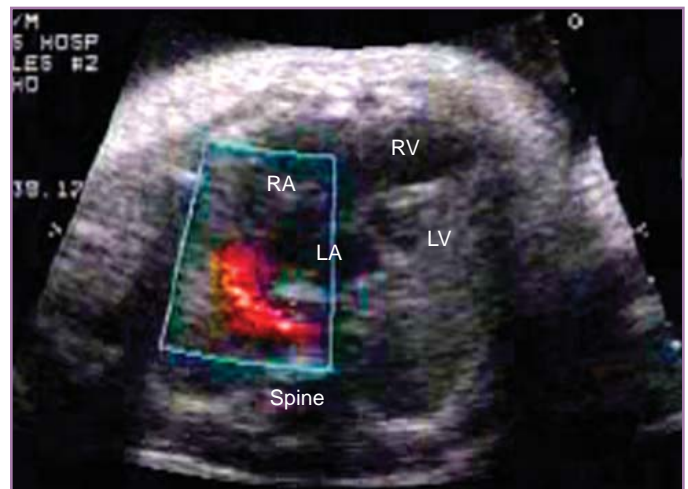


FIGURE 19-33 Fetal echocardiographic transverse image of supracardiac total anomalous pulmonary venous return. Color flow imaging demonstrates the pulmonary confluence draining continuously toward the right atrium. LA, left atrium; LV, left ventricle; RA, right atrium; RV, right ventricle.

which similarly presents a diagnostic challenge prenatally. Fortunately, most infants with scimitar syndrome do quite well, and neonatal intervention is rarely required.

Sinus venosus ASDs (discussed in more detail later) typically occur in association with anomalous pulmonary venous return of one or both right-sided pulmonary veins to the superior vena cava. Although affected fetuses may not present with right heart disproportion, the ASD high in the atrial septum may be detectable prenatally, with an absent superior rim of the atrial septum. Color flow imaging may demonstrate anomalously draining right-sided pulmonary veins. Sinus venosus defects do not generally require intervention during infancy;

ultimately, however, closure of the defect is required, with baffling of the right-sided pulmonary venous drainage to the left atrium.

Total Anomalous Pulmonary Venous Return

TAPVR can usually be diagnosed prenatally.¹⁵⁹⁻¹⁶¹ Although right heart disproportion is present in many cases, in others it is minimal or absent.¹⁶¹ However, affected fetuses do not have the normal infolding of tissue between the left atrial appendage and left pulmonary vein, and color flow imaging will demonstrate absence of pulmonary venous return to the left atrium. Other prenatal sonographic findings in TAPVR depend on the specific type of TAPVR and associated cardiac or extracardiac abnormalities.^{110,157} With intracardiac TAPVR, the pulmonary veins drain to the coronary sinus, causing the coronary sinus to be markedly dilated. Infradiaphragmatic TAPVR may manifest as a dilated IVC, because the pulmonary veins turn below the diaphragm and form a common vein before draining into the IVC. The descending vein, which typically partially obstructs within the liver, should be evaluated with color flow imaging (see Fig. 19-32). Finally, in cases of supracardiac TAPVR, 2D and color flow imaging may demonstrate a large common vein draining cephalad toward a left-sided vertical vein or toward a right-sided superior vena cava¹⁶⁰ (see Fig. 19-33).

Obstructed forms of TAPVR (infradiaphragmatic and some cases of supracardiac TAPVR) usually manifest in the immediate neonatal period with respiratory distress and cyanosis. In such instances, prostaglandin is contraindicated, despite the presence of cyanotic CHD, because the result would be exacerbation of pulmonary venous obstruction and edema. Infants with obstructed forms of TAPVR (usually infradiaphragmatic) are at risk for pulmonary hypertension and usually require surgical repair relatively emergently as newborns. For this reason, delivery should be performed at facilities prepared to manage such high-risk cases. Obstructed TAPVR carries a guarded prognosis, but infants who do well with the initial surgical intervention may have a good long-term prognosis in the absence of significant pulmonary hypertension. Nonobstructed forms of TAPVR usually require repair during infancy, although typically not emergently; occasionally, repair may be postponed for several months.

Septal Defects

This section discusses ASD and VSD, two of the most common forms of CHD. Prenatally, the aortic isthmus normally shunts flow between the right and left heart distributions. The foramen ovale allows oxygenated blood flow to stream from right atrium to left atrium, and the ductus arteriosus directs the majority of right ventricular output toward the fetal body, away from the high-resistance pulmonary circuit. Postnatally, the ductus arteriosus closes via constriction, and the foramen ovale closes via pressure-related closure of a one-way valve or flap-door. Thus, the normal fetus has a right-to-left atrial shunt, as well as a patent ductus arteriosus, but never a communication between right and left ventricles.

Atrial Septal Defect

A secundum ASD represents a deficiency of the middle portion of the atrial septum, in the same general location as the normal foramen ovale. Prenatally differentiating a normal foramen ovale from a secundum ASD can be challenging, if not impossible. Even postnatally, this distinction can be difficult to make. A secundum ASD results, embryologically, from either inadequate development of the septum secundum or excessive resorption of the septum primum. Unlike most forms of CHD, the secundum ASD occurs far more commonly in females than in males. During the second and third trimesters, the flap of the

foramen ovale (septum primum) becomes progressively more aneurysmal and more deviated into the left atrium. In some cases, the flap appears more aneurysmal than normal for gestational age, or the foramen itself appears to occupy a greater proportion of the atrial septum than normal. In such cases, a detailed evaluation for associated cardiac abnormalities, such as right heart obstruction in the case of excessive deviation, should be performed. However, no convincing association has yet been demonstrated between an abnormal prenatal appearance of the foramen ovale and the postnatal diagnosis of a true secundum ASD. Fortunately, isolated ASDs, which are probably more common than currently suspected, usually close spontaneously and rarely require intervention during infancy. If the foramen ovale does appear abnormal prenatally, particularly in association with other cardiac abnormalities or other risk factors for fetal heart disease, elective postnatal echocardiography would be prudent.

Sinus venosus ASDs occur far less commonly than secundum ASDs, and they typically occur in conjunction with anomalous return of the right-sided pulmonary veins to the superior vena cava or right atrium. Unlike secundum ASDs, sinus venosus defects may be readily diagnosed prenatally by demonstrating absence of the superior rim of the atrial septum. Moreover, the right-sided pulmonary veins occasionally may be demonstrated to drain anomalously to the superior vena cava on 2D and color flow imaging. Like secundum ASDs, these defects rarely require any neonatal intervention. Unlike secundum ASDs, however, sinus venosus defects never close spontaneously, and they typically require surgical repair electively during the first 5 years of life. Long-term prognosis is excellent.

The most important ASDs to detect prenatally are the ostium primum ASDs, which are common, always require surgery, and frequently are associated with trisomy 21. These defects can and should be readily detected, even on a standard fetal ultrasound study. Ostium primum defects result from failure of fusion of the septum primum with the endocardial cushions. These defects, also known as partial atrioventricular canal (AVC) defects, commonly occur in conjunction with a cleft mitral valve. However, the most reliable and consistent prenatal sonographic finding is absence of the lower, inferior portion of the atrial septum. Care should be taken to avoid false-positive diagnoses, because posterior/inferior angulation of the probe from the 4CV opens up a longitudinal view of the coronary sinus (see Figs. 19-11 and 19-14), which may appear similar to an ostium primum ASD. The distinction may be made simply with anterior/superior angulation of the probe: A true ostium primum ASD is evident on a true 4CV, whereas the coronary sinus should mimic this defect only with posterior/inferior angulation.

The diagnosis of an ostium primum ASD carries prenatal and postnatal implications. First, these defects carry an increased risk for trisomy 21,^{23,30} so karyotype analysis may be indicated. Second, ostium primum ASDs commonly occur in conjunction with other cardiac and extracardiac abnormalities, so detailed prenatal evaluation should be performed. Finally, isolated defects generally do not require neonatal intervention, but they uniformly require surgical repair, usually during the first 5 years of life. Long-term prognosis is usually excellent, although abnormalities of the mitral valve rarely can persist and may require additional medical or surgical attention.

Ventricular Septal Defect

VSDs probably represent the most common form of CHD, excluding patent ductus arteriosus and bicommissural aortic valve. The size and type (location) of a VSD and its associated cardiac abnormalities, if any, dictate both the prenatal and postnatal clinical implications and the approach to, and feasibility of, prenatal detection.

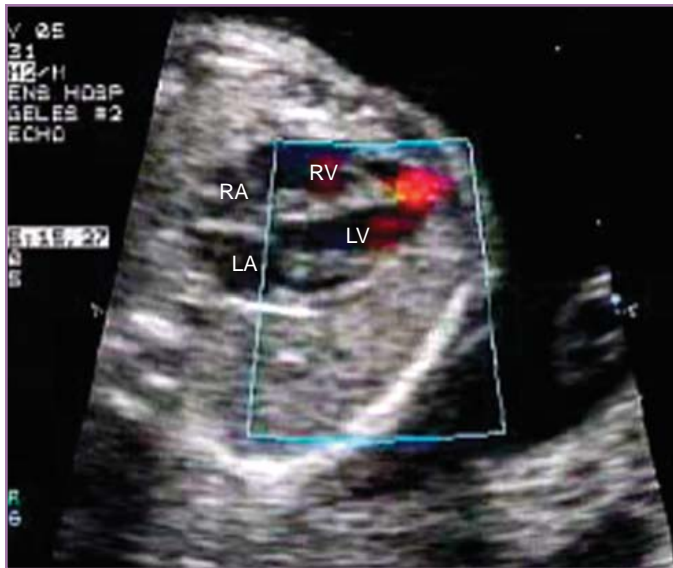


FIGURE 19-34 Fetal echocardiographic image of the four-chamber view. Color flow imaging demonstrates a small apical ventricular septal defect with left-to-right shunting. LA, left atrium; LV, left ventricle; RA, right atrium; RV, right ventricle.

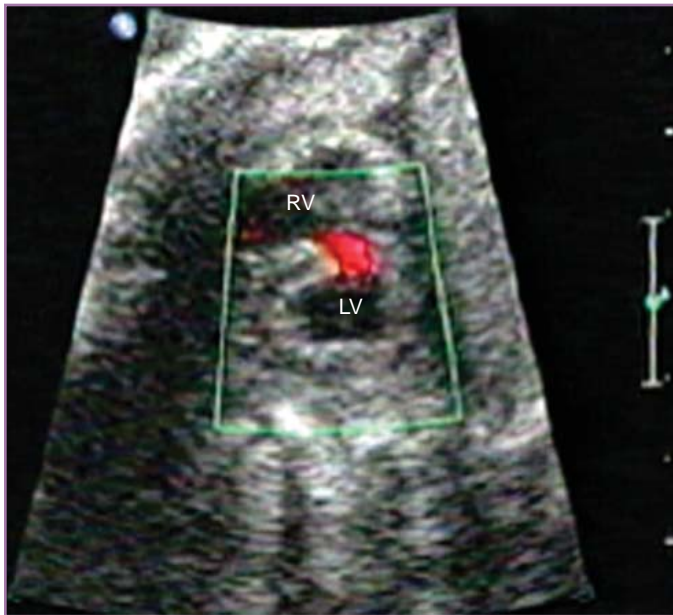


FIGURE 19-35 Fetal echocardiographic image of apical short-axis view. Color flow imaging demonstrates a moderate-sized mid-muscular ventricular septal defect with left-to-right shunting. LV, left ventricle; RV, right ventricle.

The most common forms of VSD (muscular and membranous) represent, fortuitously, the only types known to close spontaneously, either prenatally or postnatally.¹⁴ Muscular VSDs may be visualized on the 4CV (Fig. 19-34) or short-axis view (Fig. 19-35). By definition, muscular VSDs do not reside immediately beneath the mitral and tricuspid valves; such inlet VSDs occur in conjunction with abnormalities of the mitral and tricuspid valves and represent an AVC type of VSD. Inlet defects, although detectable on the 4CV, do not close spontane-

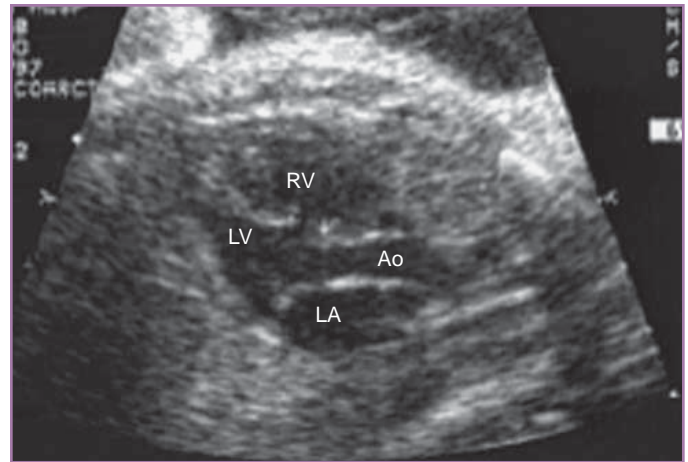


FIGURE 19-36 Fetal echocardiographic image of membranous ventricular septal defect seen in left ventricular long-axis view. Ao, aorta; LA, left atrium; LV, left ventricle; RV, right ventricle.

ously and usually require surgery. Such inlet defects are discussed in detail in the next section.

Muscular VSDs may be demonstrated with 2D imaging if they are moderate or large, but small ones may be difficult to detect without color flow imaging. Color flow imaging helps confirm the diagnosis, but spectral Doppler evaluation should also be performed. Muscular VSDs, like membranous VSDs, usually shunt predominantly left-to-right prenatally (see Figs. 19-34 and 19-35); predominant right-to-left shunting should prompt further evaluation for right-sided obstructive lesions. Small or moderate muscular defects may close prenatally or within the first few years after delivery.

Large, muscular defects manifest in infancy with tachypnea and failure to thrive and may require surgical closure during the first year of life. Because muscular defects occur within a heavily trabeculated portion of the ventricular septum, effective surgical closure can be difficult to achieve. Alternative approaches include pulmonary artery banding, followed by removal of the band once the defect has decreased in size; or, rarely, such VSDs may be closed percutaneously with a device. The long-term prognosis is usually excellent unless delayed surgery has allowed the development of pulmonary vascular disease.

Membranous VSDs, like muscular VSDs, may close spontaneously. However, unlike muscular VSDs, they cannot be visualized on the 4CV. The membranous septum resides anteriorly, a small distance beneath the aortic valve. A left ventricular long-axis view of the LVOT represents the ideal approach for visualizing a membranous VSD (Fig. 19-36). Moreover, because false-positive dropout through the thin (i.e., membranous) septum occurs commonly when the ultrasound beam is oriented parallel with the septum, the diagnosis can best be confirmed with the ultrasound beam perpendicular to the ventricular septum. Small defects may be missed, although color flow imaging and spectral Doppler evaluation are helpful for both prenatal detection and confirmation. Because of the proximity of the membranous septum to the aortic valve, membranous VSDs may cause the gradual development of aortic regurgitation, with or without prolapse of one or more aortic cusps into the defect. Although most membranous VSDs close spontaneously, larger defects may require surgical closure within the first year in infants with failure to thrive or progressive aortic regurgitation. Long-term prognosis is usually excellent unless irreversible

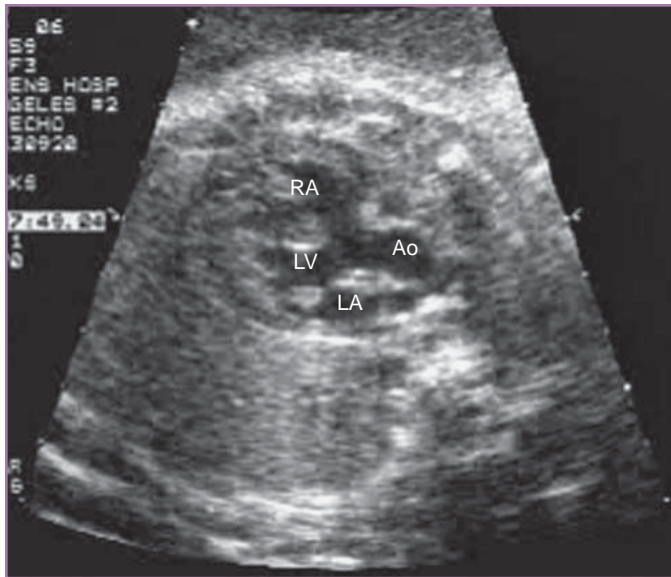


FIGURE 19-37 Fetal echocardiographic image of tetralogy of Fallot seen in left ventricular long-axis view. The aorta overrides the crest of the ventricular septum. Ao, aorta; LA, left atrium; LV, left ventricle; RV, right ventricle.

damage to the aortic valve has occurred. In such cases, aortic valve repair or even replacement may be necessary.

Subarterial VSDs commonly occur in conjunction with other cardiac abnormalities. These defects never close spontaneously and cannot be seen on the 4CV; prenatal detection requires evaluation of the outflow tracts. Subarterial defects may be predominantly under the aortic valve (subaortic) or the pulmonary valve (subpulmonary). Unlike membranous VSDs, which occur close to, but not immediately beneath, the aortic valve, subarterial defects occur immediately beneath one or both semilunar valves. These defects almost invariably require surgical correction within the first year of life. The prognosis, although generally good, relates in part to associated cardiac abnormalities and to any residual aortic or pulmonary pathology.

Malalignment VSDs occur when the upper (conal/infundibular) portion of the ventricular septum separates from the rest of the septum and deviates either anteriorly into the RVOT or posteriorly into the LVOT. Malalignment VSDs secondary to anterior deviation of the conal septum generate RVOT obstruction (subvalvar and valvar pulmonary stenosis and pulmonary artery hypoplasia); TOF is the most common manifestation of such a defect (Figs. 19-37 and 19-38). In contrast, posterior malalignment of the conal septum generates a malalignment VSD in association with LVOT obstruction (e.g., aortic stenosis, bicommissural aortic valve, aortic arch hypoplasia, coarctation of the aorta) (Fig. 19-39). Like subarterial VSDs, malalignment VSDs may appear normal on 4CV, but both the VSD and its associated outflow tract abnormalities should be seen with outflow tract imaging. Management and prognosis depend on the type and severity of outflow tract obstruction. Severe malalignment in either direction may generate severe enough outflow tract obstruction to require maintenance of ductal patency (with prostaglandin) after delivery.

Atrioventricular Canal Defect

Normally, during embryonic development, the septum primum and the endocardial cushions fuse together. Abnormal development of

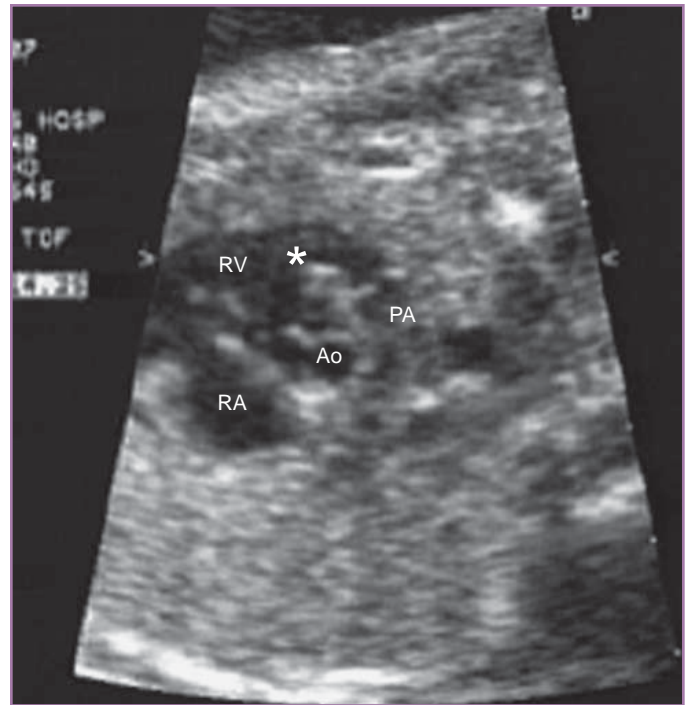


FIGURE 19-38 Fetal echocardiographic image of tetralogy of Fallot seen in apical short-axis view. The conal septum (*asterisk*) deviates anteriorly into the right ventricular outflow tract, causing subvalvar pulmonary stenosis, aortic override, and an anterior malalignment ventricular septal defect. Note that the pulmonary valve appears smaller than the aortic valve. Ao, aorta; PA, pulmonary artery; RA, right atrium; RV, right ventricle.

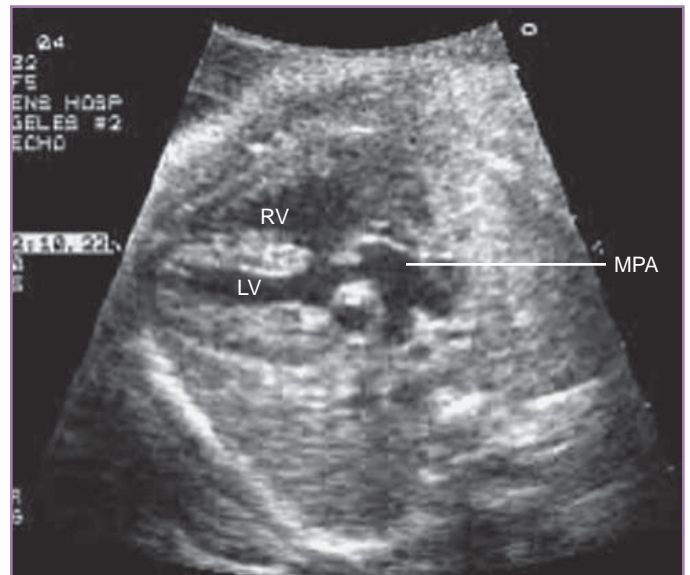


FIGURE 19-39 Fetal echocardiographic image of transposition with subvalvar and valvar pulmonary stenosis seen in left ventricular long-axis view. The conal septum deviates posteriorly into the left ventricular outflow tract, causing subvalvar pulmonary stenosis and a posterior malalignment ventricular septal defect. With normally related great arteries, posterior malalignment of the conal septum would cause aortic rather than pulmonary obstruction. LV, left ventricle; MPA, main pulmonary artery; RV, right ventricle.

these structures results in several forms of AVC defect, all of which should be detected with standard fetal screening ultrasound evaluations as well as with detailed fetal echocardiography. Moreover, all forms of AVC defects ultimately require surgical intervention, and most have relatively high associations with trisomy 21^{23,30} or other cardiac abnormalities.¹⁶² The prognosis is generally good but depends on the associated cardiac and extracardiac abnormalities,¹⁶³ as well as postoperative mitral, tricuspid, and ventricular function.

Partial Atrioventricular Canal Defect

In partial AVC defects, the septum primum fails to fuse with the endocardial cushions. As a result, the fetal heart develops an ostium primum ASD and, typically, a cleft in the mitral valve (with some degree of mitral regurgitation). In part because of this defect's close association with trisomy 21 or heterotaxy,^{23,30,162} great care should be taken not to miss a partial AVC defect on routine screening ultrasonography. Partial AVC defects may be readily detected in the 4CV by the conspicuous absence of the septum primum (the lowest, most inferior portion of the atrial septum). Moreover, the absence of an atrioventricular septum results in absence of the normal apical displacement of the septal leaflet of the tricuspid valve; instead, the septal leaflets of the mitral and tricuspid valves insert onto the ventricular septum at the same level. Care should be taken not to confuse this defect with a dilated coronary sinus (usually secondary to a persistent LSVC), which would be seen in a plane immediately posterior/inferior to the 4CV (see Figs. 19-11 and 19-14).¹⁰⁷ True AVC defects will be noted with anterior/superior angulation of the probe from the level of the coronary sinus into a true 4CV.

Partial AVC defects manifest clinically similar to secundum ASDs, usually with a heart murmur in an asymptomatic child between 2 months and 2 years of age. Many patients have trisomy 21³⁰ or other cardiac disease (heterotaxy).¹⁶² The cleft in the mitral valve typically does not generate signs or symptoms unless it is associated with more severe degrees of mitral regurgitation. The long-term prognosis after surgical closure during the first several years of life is usually excellent, unless significant mitral valve pathology persists.

Complete Atrioventricular Canal Defect

In complete AVC defects, the endocardial cushions fail to fuse, and the septum primum fails to fuse with the endocardial cushions. As a result, the fetal heart has not only an ostium primum ASD and cleft mitral valve but also a large inlet VSD (contiguous with the ostium primum ASD) and a single, common atrioventricular valve. This type of AVC defect should be readily detected with a routine 4CV (Figs. 19-40 and 19-41). Although isolated forms of complete AVC defects carry an exceptionally high association with trisomy 21,^{23,30} complete AVC defects in association with other cardiac abnormalities carry a high association with heterotaxy syndrome.^{162,163} Beyond the diagnosis of complete AVC defect, detailed fetal echocardiographic evaluation should include assessment of atrioventricular valvar regurgitation using color flow imaging and close attention to the relative development of both ventricles and possible outflow tract obstruction.

When complete AVC defects occur with well-balanced right and left ventricles (so-called balanced complete AVC), corrective surgery may be offered at 3 to 6 months of age. Such patients usually have an excellent long-term prognosis in the absence of severe residual atrioventricular valve regurgitation. On the other hand, the fetus with a hypoplastic right ventricle (left ventricle–dominant AVC) (Fig. 19-42) or a hypoplastic left ventricle (right ventricle–dominant AVC) is likely to require single-ventricle palliation, meaning three palliative surgical procedures within the first 2 to 3 years of life. Some of these patients

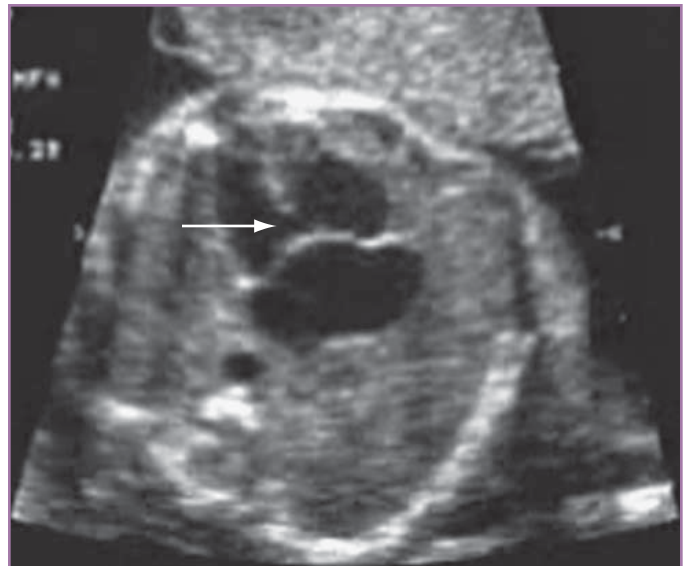


FIGURE 19-40 Fetal echocardiographic image of four-chamber view demonstrating a balanced complete atrioventricular canal defect. During systole, the common atrioventricular valve is closed, and the large atrial and ventricular (arrow) defects are readily apparent. Note the absence of the septum primum.

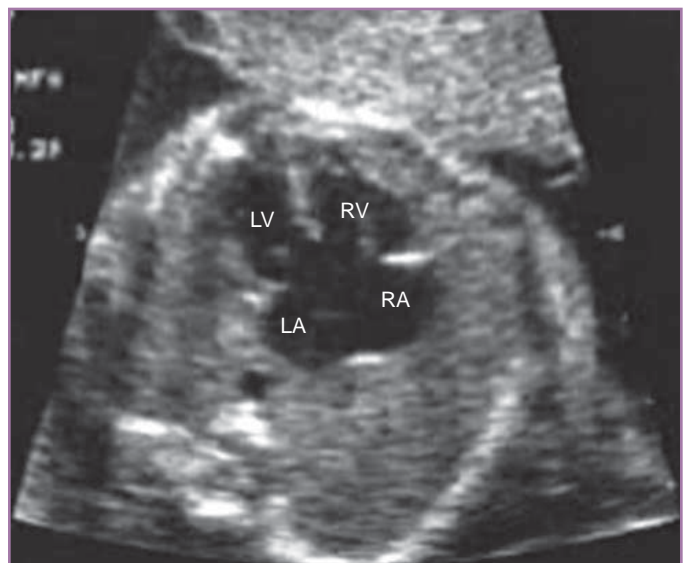


FIGURE 19-41 Fetal echocardiographic image of four-chamber view demonstrating a balanced complete atrioventricular canal defect. During diastole, the common atrioventricular valve is open, and the large atrial and ventricular defects (in continuity) are readily apparent. LA, left atrium; LV, left ventricle; RA, right atrium; RV, right ventricle.

may undergo early pulmonary artery banding (during the first month after delivery), to provide a controlled source of pulmonary blood flow for the first 6 months and to avoid the development of pulmonary vascular disease. Because single-ventricle palliation involves rerouting of the systemic venous return through the lungs without the benefit of a subpulmonary ventricle, elevated pulmonary vascular resistance may be considered a relative contraindication (or at least a risk factor) for subsequent palliative procedures (i.e., Glenn and Fontan proce-

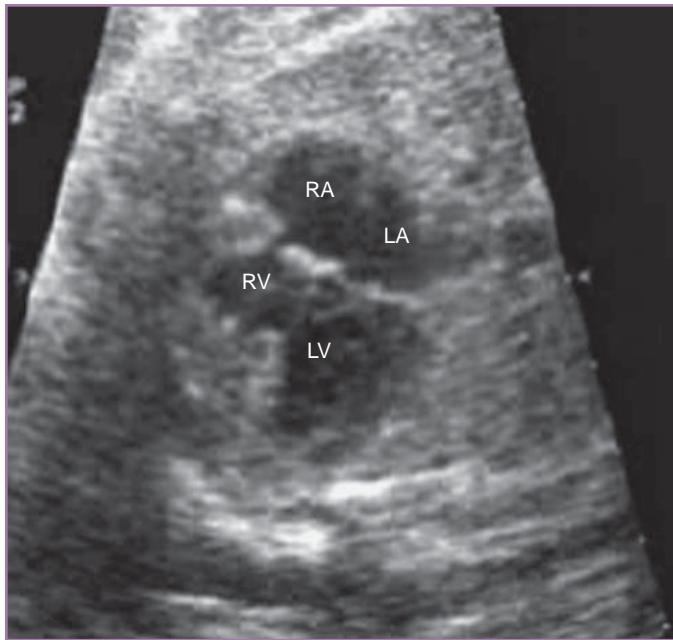


FIGURE 19-42 Fetal echocardiographic image of four-chamber view demonstrating an unbalanced, left ventricle-dominant atrioventricular canal. Note the large primum atrial septal defect and large inlet ventricular septal defect, as well as the hypoplastic right ventricle (RV). LA, left atrium; LV, left ventricle; RA, right atrium.

dures, which redirect, respectively, the superior vena cava or the IVC directly to the right pulmonary artery). In the best of cases, the patient with an unbalanced complete AVC defect faces a much more guarded, palliated long-term prognosis than the patient with a balanced complete AVC defect. Therefore, making such a distinction in a fetus is of great importance.

Transitional Atrioventricular Canal Defect

A transitional AVC defect should be recognized readily from the 4CV. Affected fetuses have an ostium primum defect and, with absence of the atrioventricular septum, the mitral and tricuspid valves insert onto the crest of the ventricular septum at the same level. The mitral valve is frequently cleft, with some degree of mitral regurgitation visualized with color flow imaging. In contrast to a complete AVC defect, transitional AVC defects may have two relatively well-formed mitral and tricuspid valves, and the inlet VSD is only small to moderate in size, largely occluded by mitral and tricuspid valve tissue. Transitional AVC defects, when balanced and not associated with other cardiac defects, typically require a single surgical procedure between 6 months and 5 years of age, and generally carry a good long-term prognosis.

Ebstein Anomaly of the Tricuspid Valve and Tricuspid Valve Dysplasia

Both fetal Ebstein anomaly of the tricuspid valve and tricuspid valve dysplasia carry a wide spectrum of potential outcomes, depending on severity.^{164,165} Fortunately, the more severe cases are those that should be most readily detected on a standard 4CV.

Tricuspid valve dysplasia refers to thickening and distortion of the tricuspid valve leaflets and supportive apparatus, with the primary pathophysiologic manifestation being tricuspid regurgitation. The more severe the tricuspid regurgitation, the more dilated the right

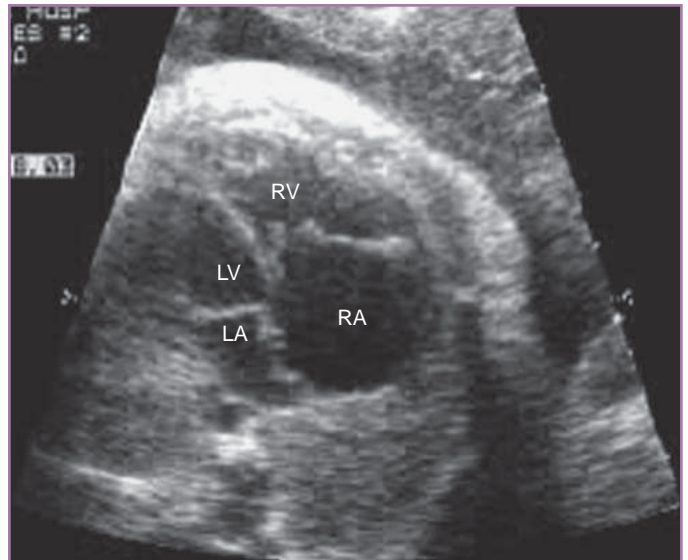


FIGURE 19-43 Fetal echocardiographic image of four-chamber view demonstrating tricuspid valve dysplasia. Note absence of apical displacement of the septal insertion site of the tricuspid valve. LA, left atrium; LV, left ventricle; RA, right atrium; RV, right ventricle.

atrium and right ventricle, the more likely the development of pulmonary valve stenosis/atresia (related to diminished antegrade flow), and the more likely the development of hydrops or pulmonary hypoplasia or both (related to elevated right atrial pressure and right-sided heart enlargement).

Sharing similar pathophysiology, Ebstein anomaly of the tricuspid valve may be considered a subset of tricuspid valve dysplasia. In Ebstein anomaly, the dysplastic tricuspid valve is partially fused against the ventricular septum, causing the coaptation point to be apically displaced within the right ventricle. Both disorders carry an association with episodic SVT and Wolff-Parkinson-White (WPW) syndrome.

Both Ebstein anomaly and tricuspid valve dysplasia may be visualized on the 4CV, with enlargement of the right side of the heart (particularly the right atrium), dysplasia of the tricuspid valve (Fig. 19-43), and apical displacement of the tricuspid valve coaptation point in the case of Ebstein anomaly (Fig. 19-44). Color flow imaging is useful to demonstrate the degree of tricuspid regurgitation (Fig. 19-45), although such information should be suspected from the degree of right atrial enlargement. In cases of severe tricuspid regurgitation, Ebstein anomaly and tricuspid valve dysplasia commonly have some degree of pulmonary valve stenosis, or even atresia, along with hypoplasia of the main and branch pulmonary arteries; such findings should be evident on evaluation of the outflow tracts.

Although Ebstein anomaly and tricuspid valve dysplasia are occasionally associated with fetal exposure to maternal lithium, most cases occur in pregnancies not identified as high risk. The risk for associated aneuploidy is probably mildly increased over that in the general fetal population. Ebstein anomaly represents a common finding in the rare setting of congenitally corrected transposition (discussed later). However, most of the time, the overriding determinants of short- and long-term survival are the degree of fetal heart failure or hydrops, the degree of pulmonary hypoplasia, and the degree of left ventricular dysfunction. Progressive fetal CHF (related to tricuspid regurgitation, SVT, and/or ventricular dysfunction) puts the fetus at risk for hydrops and fetal demise. Newborns with a history of hydrops prenatally may present with diffuse edema or anasarca, and they face significant

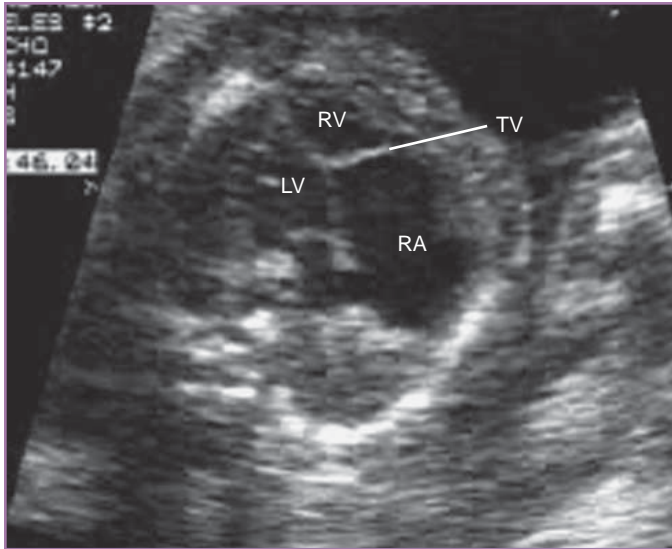


FIGURE 19-44 Fetal echocardiographic image of four-chamber view demonstrating Ebstein anomaly of the tricuspid valve. Note apical displacement of the septal insertion site of the tricuspid valve. Compare with Figure 19-43. LV, left ventricle; RA, right atrium; RV, right ventricle; TV, tricuspid valve.

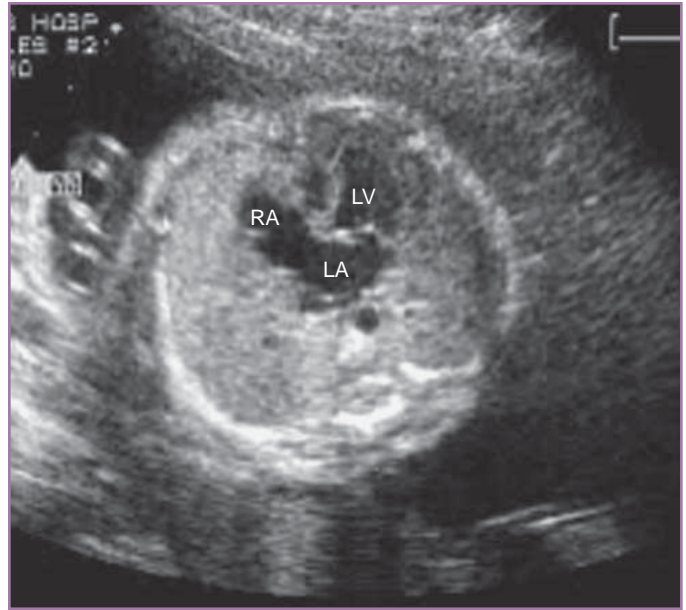


FIGURE 19-46 Fetal echocardiographic image of four-chamber view demonstrating tricuspid atresia. Note hypoplastic right ventricle, atretic and membranous tricuspid valve, and bowing of the atrial septum laterally into the left atrium. LA, left atrium; LV, left ventricle; RA, right atrium.

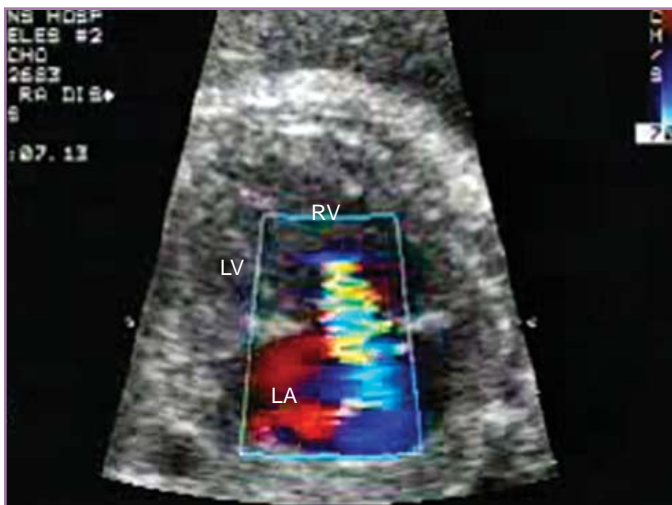

FIGURE 19-45 Fetal echocardiographic image of four-chamber view demonstrating Ebstein anomaly of the tricuspid valve. Color flow imaging demonstrates tricuspid regurgitation jet arising from within the right ventricle. LA, left atrium; LV, left ventricle; RV, right ventricle.

neonatal morbidity and mortality. Pulmonary hypoplasia, related to marked cardiomegaly, particularly early in gestation, represents the other primary determinant of neonatal survival and may not always be accurately predicted with prenatal assessments. Fetuses with moderate or severe forms of Ebstein anomaly or tricuspid valve dysplasia should be delivered at centers that can provide optimal medical and surgical care for high-risk neonates.

Tricuspid Atresia

Tricuspid atresia represents the most basic form of single ventricle and generally carries the best long-term prognosis among single-ventricle

disorders. In tricuspid atresia, the tricuspid valve either is not formed or otherwise simply does not open. As a result, all flow entering the right atrium must cross the foramen ovale into the left atrium and, from there, into the left ventricle. From the left ventricle, some portion of the blood exits via the aortic valve, and some passes through a VSD (usually present with tricuspid atresia) and into the pulmonary artery. Because flow into the right ventricle and pulmonary artery must come via the VSD, the right ventricle and pulmonary artery generally appear hypoplastic, and the pulmonary valve is usually stenotic, if not atretic. However, when tricuspid atresia occurs in conjunction with transposition of the great arteries (TGA), the pulmonary valve and pulmonary artery (in this case arising from the left ventricle) are usually well formed, whereas the aortic valve may be stenotic, with a hypoplastic aortic arch and possible coarctation.

In the fetus, tricuspid atresia manifests with an abnormal 4CV (Fig. 19-46), including an abnormal (or absent) tricuspid valve and hypoplastic right ventricle.¹⁶⁶ Rarely, color flow imaging demonstrates the foramen ovale to be restrictive to flow. The outflow tracts also demand close attention, given the close association of tricuspid atresia with TGA or with underdevelopment of the great artery arising from the right ventricle, or both.

After delivery, most affected babies appear cyanotic, but ductal dependency is determined by the amount of pulmonary blood flow (in normally related great arteries) or by the presence of aortic stenosis, coarctation, or inadequate mixing (in TGA). Infants with tricuspid atresia ultimately require palliation with a Glenn procedure (anastomosis of the cephalic end of the superior vena cava to the right pulmonary artery, usually at about 6 months of age) followed by a Fontan procedure (anastomosis of the IVC directly to the right pulmonary artery with interposition graft, usually at 2 to 3 years of age). Whether a neonatal shunt or arch repair is needed depends on the details of the anatomy and pathophysiology. Long-term prognosis for tricuspid atresia tends to be better than for other forms of single ventricle, but

the child will still have increasing risks for heart failure and arrhythmias and possible need for cardiac transplantation in later decades.

Pulmonary Atresia with Intact Ventricular Septum

In pulmonary atresia with intact ventricular septum, the RVOT ends blindly (pulmonary atresia). As a result, during fetal life, the right side of the heart must direct its share of cardiac output entirely through the foramen ovale. In the presence of a competent tricuspid valve (which is typical), the right ventricle hypertrophies in response to the high pressure generated by absence of egress. This lesion may result, in some cases, from prenatal progression of pulmonary stenosis to pulmonary atresia.¹⁶ The right ventricle, along with its tricuspid valve, typically develops some degree of hypoplasia. Those fetuses with markedly elevated right ventricular pressure may develop sinusoidal connections between the right ventricular cavity and the coronary arteries. Such sinusoids may occur in association with significant coronary artery stenoses, placing these patients at risk for acute myocardial infarction.

Pulmonary atresia with intact ventricular septum usually manifests in fetal life with an abnormal 4CV (Figs. 19-47 and 19-48), including an abnormal-appearing tricuspid valve and a hypoplastic, hypertrophied, poorly functioning right ventricle. Occasionally, the degree of tricuspid valve and right ventricular hypoplasia is mild enough to be missed on a cursory 4CV; other cases may mimic tricuspid atresia (compare Figs. 19-46 and 19-47). Color flow imaging should be used to evaluate the tricuspid valve for evidence of tricuspid regurgitation.

Color flow imaging may also detect significant sinusoids within the ventricular septum or right ventricular free wall or both. Careful evaluation of the 4CV in real time should almost always detect some abnormality in size, structure, or function of the tricuspid valve or right ventricle. Imaging of the outflow tracts should invariably demonstrate the pulmonary valve to be atretic, with no prograde flow from right ventricle to pulmonary artery. Detailed cardiac imaging should include evaluation of the continuity and size of the main and branch pulmonary arteries, supplied retrograde through the ductus arteriosus.

After delivery, babies with this lesion require prostaglandin to maintain patency of the ductus arteriosus for pulmonary blood flow. Neonatal surgery is always necessary; it usually includes placement of a shunt, and sometimes reconstruction of the RVOT. Long-term prognosis varies from an excellent two-ventricle repair to single-ventricle palliation, and those patients with coronary artery abnormalities face additional short- and long-term risks of myocardial infarction. Some fetal echocardiographic parameters, including tricuspid valve size and the presence of tricuspid regurgitation, can help predict outcome.^{167,168}

Hypoplastic Left Heart Syndrome

One of the most common and most feared cardiac diagnoses, HLHS represents a heterogeneous constellation of various forms of CHD, the result of which in the newborn infant is a left heart with a surgically resistant inability to sustain systemic cardiac output. Most cases of HLHS carry an increased risk for congenital or acquired central nervous system abnormalities,^{41,169} as well as some increased risk for

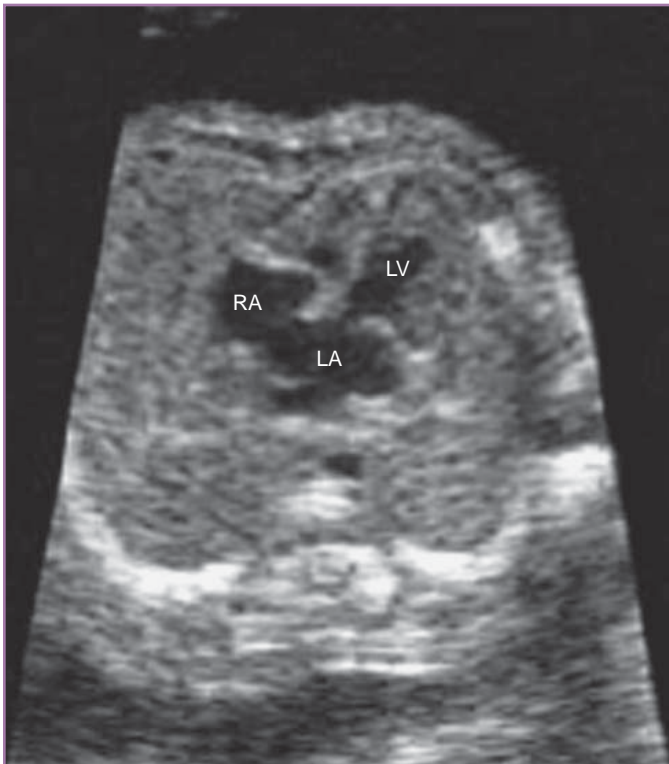

FIGURE 19-47 Fetal echocardiographic image of four-chamber view demonstrating pulmonary atresia with intact ventricular septum. Note similarity to tricuspid atresia (Figure 19-46), but with a more normal appearance to the tricuspid valve. LA, left atrium; LV, left ventricle; RA, right atrium.

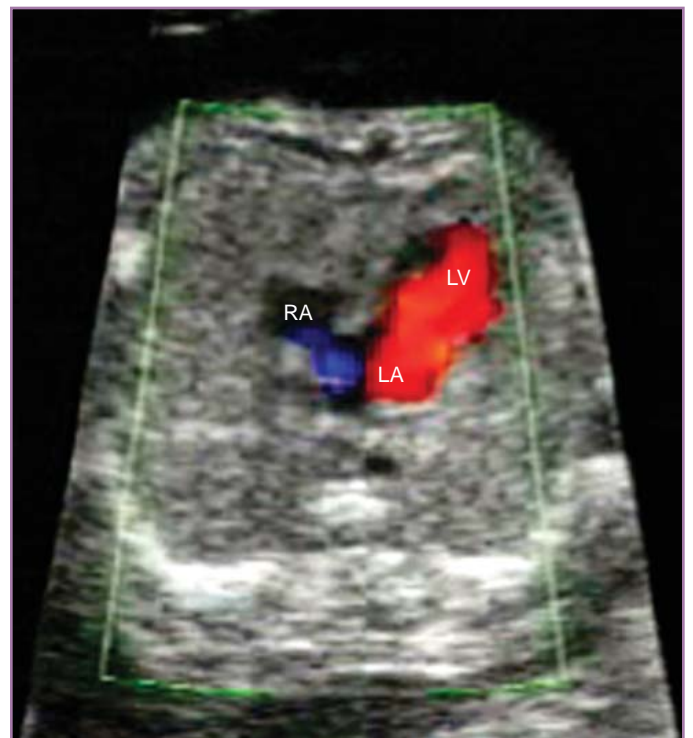


FIGURE 19-48 Fetal echocardiographic image of four-chamber view of fetus with pulmonary atresia with intact ventricular septum. Color flow imaging demonstrates absence of prograde flow across the tricuspid valve during diastole and right-to-left flow across the atrial septum. LA, left atrium; LV, left ventricle; RA, right atrium.

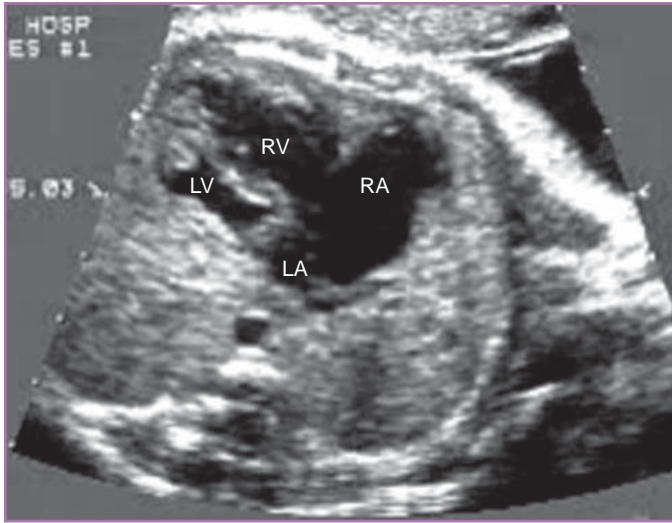


FIGURE 19-49 Fetal echocardiographic image of four-chamber view demonstrating hypoplastic left heart syndrome with mitral atresia and ventricular septal defect. The ventricular septal defect, although not visualized, may be inferred from the presence of a moderately well-formed left ventricle with mitral atresia. LA, left atrium; LV, left ventricle; RA, right atrium; RV, right ventricle.

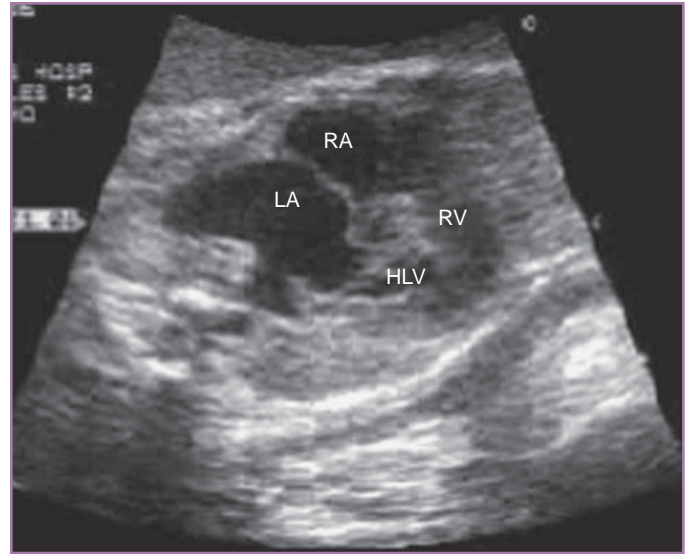


FIGURE 19-50 Fetal echocardiographic image of four-chamber view demonstrating hypoplastic left heart syndrome with restrictive foramen ovale. The left atrium and pulmonary veins appear dilated in response to left atrial hypertension (lack of egress of pulmonary venous return from left atrium). HLV, hypoplastic left ventricle; LA, left atrium; RA, right atrium; RV, right ventricle.

aneuploidy. Some forms of multiple left-sided obstructive lesions (e.g., Shone syndrome) may be corrected with surgical procedures addressing the left ventricular inflow tract, outflow tract, and aortic arch; these cases do not qualify as HLHS. Although this distinction is of tremendous clinical importance, it sometimes is subtle, even postnatally.

This section discusses the most common and classic form of HLHS, mitral and aortic atresia, with the caution that other forms of HLHS may differ in their prenatal appearance and postnatal course. Mitral or aortic stenosis, for example, may manifest with a relatively well-formed left ventricle at mid-gestation but with HLHS at term.^{16,82,170} In fetuses with mitral and aortic atresia, there is a markedly abnormal 4CV at mid-gestation, with no inflow into the left ventricle (effectively no mitral valve) and a severely hypoplastic left ventricle (Fig. 19-49; see Fig. 19-24). The foramen ovale needs close prenatal evaluation with 2D and color flow imaging, because restriction to flow (left-to-right) may lead to pulmonary venous congestion (Fig. 19-50) and irreversible pulmonary vascular disease.¹⁷¹ Such restriction to flow occasionally may not develop until late in the third trimester. Some fetuses with HLHS and a restrictive foramen ovale may be candidates for percutaneous enlargement of the foramen ovale during the second trimester, with the hope of avoiding the development of pulmonary vascular disease and improving long-term survival.¹⁷¹ The aortic arch fills retrograde from the ductus arteriosus (Fig. 19-51), and may be visualized with both 2D and color flow imaging. Tricuspid valve and right ventricular structure and function also require close evaluation, using both 2D and color flow imaging to assess for tricuspid regurgitation and right ventricular dysfunction.

The fetus with HLHS should be delivered at a tertiary care center experienced with complex CHD in newborns. All newborns with HLHS, by definition, are ductal dependent for systemic blood flow, so prostaglandin infusion should be initiated. Supplemental oxygen generally should be avoided, because in these patients it usually worsens pulmonary overcirculation and systemic hypoperfusion. The newborn with HLHS and a restrictive foramen ovale may require emergent atrial

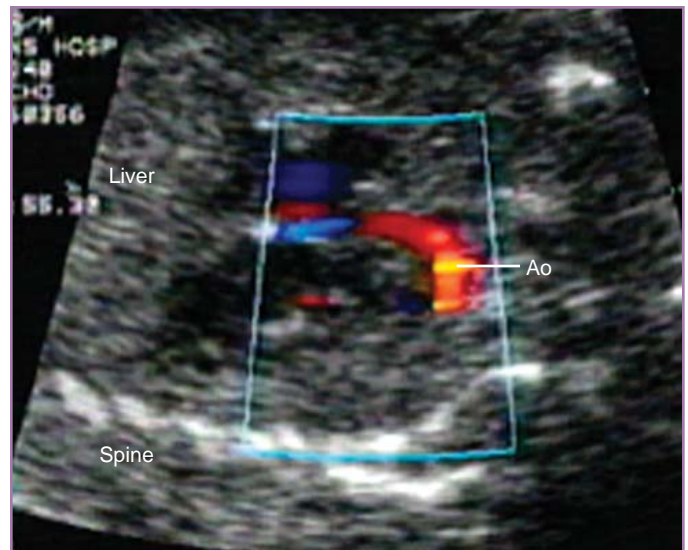


FIGURE 19-51 Fetal echocardiographic sagittal image of aortic arch in fetus with hypoplastic left heart syndrome. Color flow imaging demonstrates pulsatile, retrograde flow into the transverse aortic arch. Ao, aortic arch.

septostomy/septectomy within the first several hours after delivery. In general, infants with HLHS require the first of three palliative surgical procedures (the Norwood operation) within the first week after delivery, followed by a Glenn procedure at approximately 6 months and a Fontan procedure at 2 to 3 years. Some patients undergo cardiac transplantation,¹⁷² and others receive comfort care only.^{172,173} With surgery, the current long-term prognosis begins with a 5-year survival rate of 75% to 80% at the best and largest centers. Although many patients do extremely well early on, long-term data are lacking because the surgical approach is so new.¹⁷²⁻¹⁷⁴ Many survivors have some degree of

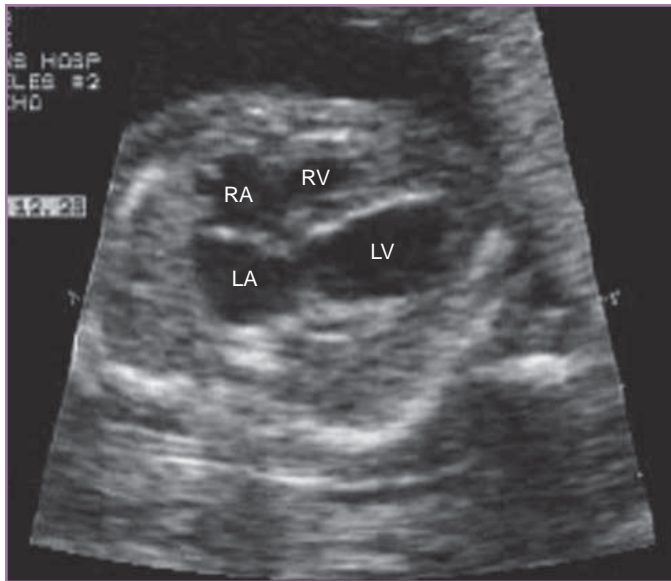


FIGURE 19-52 Fetal echocardiographic image of four-chamber view demonstrating a dilated left ventricle with endocardial fibroelastosis in a fetus with severe aortic stenosis. Note the presence of left-sided heart disproportion. LA, left atrium; LV, left ventricle; RA, right atrium; RV, right ventricle.

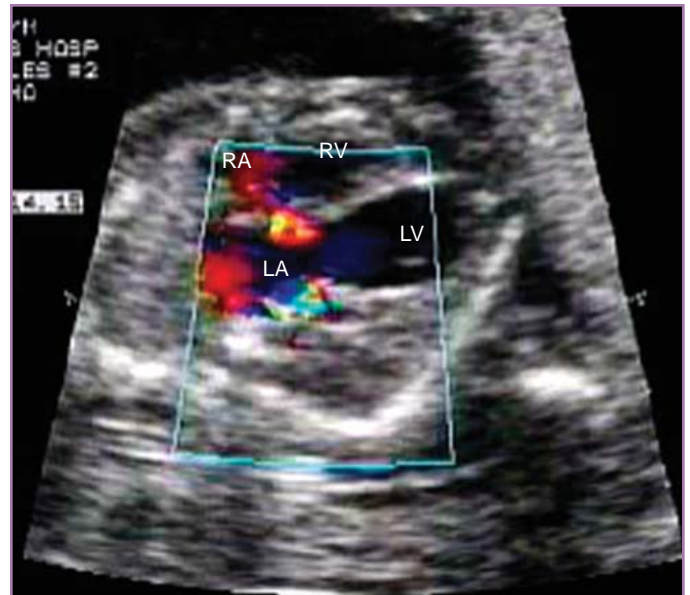


FIGURE 19-53 Fetal echocardiographic image of four-chamber view demonstrating a dilated left ventricle with endocardial fibroelastosis in a fetus with severe aortic stenosis. Color flow imaging demonstrates mitral regurgitation and left-to-right flow across the foramen ovale. LA, left atrium; LV, left ventricle; RA, right atrium; RV, right ventricle.

neurodevelopmental delay.^{41,169} Long-term survivors with progressive right-sided heart failure may require cardiac transplantation during adulthood.

Valvar Aortic Stenosis

Valvar aortic stenosis, usually secondary to a thickened, bicommissural aortic valve, represents one of the most common lesions known to have the potential to evolve dramatically during the second and third trimesters.¹⁶ Severe cases of valvar aortic stenosis, particularly if present by 18 to 20 weeks' gestation, may adversely affect the prenatal development of the left ventricle, potentially generating a form of dilated cardiomyopathy that then evolves into HLHS.^{170,175} All degrees of valvar aortic stenosis may occur in conjunction with coarctation of the aorta. From a flow-related explanation of CHD, either lesion may actually cause the other.

Mild to moderate valvar aortic stenosis may be detected prenatally by visualization of a thickened, usually small aortic valve on imaging of the LVOT. The 4CV view typically appears normal. Spectral and color flow Doppler imaging may demonstrate flow acceleration with an increased velocity in the ascending aorta; rarely, this lesion may also have some degree of aortic regurgitation.

Severe forms of valvar aortic stenosis may manifest during the second trimester with abnormalities of both the 4CV and the outflow tracts. The 4CV may include a dilated, poorly functioning left ventricle (Fig. 19-52); in some cases, diminished diastolic excursion of the mitral valve, mitral valve regurgitation, and, often, endocardial fibroelastosis (brightened left ventricular endocardium) are present. The foramen ovale may shunt predominantly left-to-right (Fig. 19-53). The outflow tract views may demonstrate a small, thickened aortic valve with diminished excursion, and color flow imaging of the aortic arch may demonstrate retrograde (see Fig. 19-51) or bidirectional flow in the transverse arch. Some cases of severe valvar aortic stenosis may evolve into HLHS by term, whereas others manifest in the newborn period

with valvar aortic stenosis and a well-formed but poorly functioning left ventricle.^{170,175}

In a subset of those cases judged most likely to evolve into HLHS, the fetus may be a candidate for second-trimester dilation of the aortic valve.^{170,175} Such fetal intracardiac interventions may prevent the development of some cases of HLHS and allow a neonatal two-ventricle repair rather than single-ventricle palliation. Some fetuses may also benefit from the procedure's ability to establish prograde, pulsatile flow to the brain. However, the procedure carries risks for both mother and fetus. Although the safety of the procedure and the ability to predict which cases will evolve into HLHS both improve with advancing gestation, the likelihood of procedural efficacy decreases with advancing gestational age. The procedure, and the data to support it, both remain inadequately developed.

After delivery, mild to moderate valvar aortic stenosis usually requires observation over months to years; transcatheter or surgical intervention is postponed until the disease has significantly progressed. In contrast, severe valvar aortic stenosis typically manifests immediately after delivery with poor left ventricular systolic and diastolic function. These newborns require prostaglandin to maintain ductal patency for systemic blood flow. Affected infants undergo, soon after birth, either transcatheter balloon dilation of the aortic valve, surgical aortic valvuloplasty, or the Ross procedure (replacement of the patient's own aortic valve with the patient's own pulmonary valve and placement of a pulmonary homograft into the patient's RVOT). Most cases of severe valvar aortic stenosis ultimately require valve replacement, but the prognosis remains quite good as long as left ventricular function recovers after the initial intervention.

Coarctation of the Aorta

Coarctation of the aorta represents not only one of the most common forms of ductal-dependent CHD but also one of the most difficult

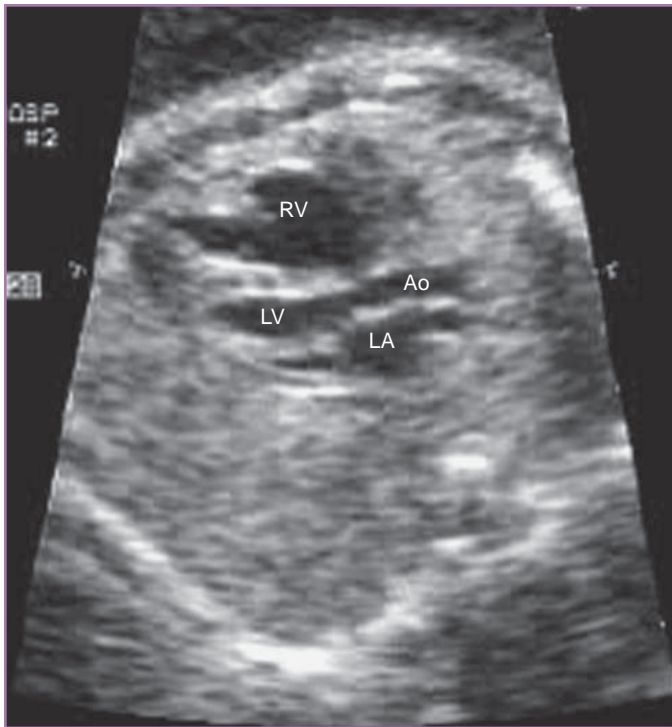

FIGURE 19-54 Fetal echocardiographic image of left ventricular long-axis view demonstrating right heart disproportion suggestive of coarctation. The presence of a bicommissural aortic valve, possibly thickened, would help to support the diagnosis of coarctation. Ao, aorta; LA, left atrium; LV, left ventricle; RV, right ventricle.

cardiac lesions to detect prenatally.^{176,177} Normally, the fetal left ventricle supplies the coronary and cerebral circulations, with only a relatively small component of left ventricular cardiac output crossing the aortic isthmus to supply the lower body. The fetal right ventricle, in contrast, normally supplies most of the lower body of the fetus, with most of the right ventricular output passing right-to-left through the ductus arteriosus and joining the descending aorta just distal to the aortic isthmus. Coarctation of the aorta represents a narrowing of the aortic isthmus, but it frequently may also involve hypoplasia of the transverse and distal aortic arches. Prenatally, coarctation may be difficult to detect as long as the ductus arteriosus remains widely patent. With closure of the ductus arteriosus postnatally, ductal tissue extending circumferentially around the descending aorta and isthmus constricts, allowing a previously unrecognized coarctation to become manifest.

As a result, the prenatal detection and diagnosis of coarctation remains challenging, particularly with relatively discrete forms of the disease.¹⁷⁶⁻¹⁷⁸ Mild and moderate forms of coarctation may appear normal prenatally. More severe forms of coarctation, however, commonly result in abnormalities of the 4CV and outflow tracts (Fig. 19-54). The right atrium and ventricle commonly appear larger than expected (right heart disproportion), probably related to redistribution of flow to the right side of the heart, and color flow imaging may detect some degree of tricuspid regurgitation. A persistent LSVc draining to the coronary sinus represents a commonly associated finding¹⁰⁸ and should increase the suspicion for coarctation of the aorta. Evaluation of the outflow tracts should again demonstrate right heart disproportion. Because a bicommissural aortic valve is another commonly

associated finding, the aortic valve may appear mildly thickened or eccentric. The aortic valve annulus, aortic root, transverse aortic arch, and aortic isthmus may all appear small. Quantitative measurements of the aortic annulus and arch may be useful.^{82,98,178} Finally, in the presence of coarctation, the third main branch of the aortic arch, the left subclavian artery, may have its origin somewhat distally displaced, closer to the isthmus than normal.

More severe forms of coarctation of the aorta represent ductal-dependent lesions requiring initiation of prostaglandin after delivery to maintain systemic cardiac output. These patients require neonatal repair, via either transcatheter dilation or surgical correction. Prenatal detection may prevent the inadvertent discharge to home of a newborn with severe coarctation whose ductus arteriosus has not yet closed.³⁹ Unless end-organ damage occurs at home before the diagnosis is made, the prognosis is generally excellent for isolated coarctation of the aorta. However, up to 50% of cases with neonatal repair require reintervention for recoarctation, and many patients, even with successful repair, have lifelong systemic hypertension.

Tetralogy of Fallot

TOF represents both the most common form of cyanotic CHD and the most common major CHD associated with a normal 4CV. Although most cases of TOF occur in isolation, TOF is also one of the most common forms of CHD associated with maternal diabetes, trisomy 21, DiGeorge syndrome,¹⁷⁹ omphalocele, and pentalogy of Cantrell, among other conditions.²³ TOF comprises a series of four cardiac findings, all believed to be related to anterior, superior, and rightward deviation of the conal septum into the RVOT. As a result of this deviation of the conal septum, TOF manifests with pulmonary stenosis, malalignment VSD, overriding aorta, and, postnatally, right ventricular hypertrophy secondary to persistent exposure of the right ventricle to systemic pressure. The detection, management, and prognosis of TOF depend on details of the anatomy and physiology. The following categories of TOF are discussed in this section: TOF with pulmonary stenosis, TOF with pulmonary atresia (TOF/PA), and TOF with absent pulmonary valve (TOF/APV).

Tetralogy of Fallot with Pulmonary Stenosis

In TOF with pulmonary stenosis, the degree of RVOT obstruction and the degree of hypoplasia of the main and branch pulmonary arteries determine the extent of cyanosis after delivery, the timing for initial surgical intervention, and, to some degree, the prognosis. The pulmonary stenosis in a fetus with TOF usually progresses prenatally, although at a variable rate.^{16,81}

In a fetus with TOF with pulmonary stenosis, the 4CV is usually normal. Occasionally, the right ventricle appears slightly dilated or hypertrophied. Evaluation of the outflow tracts demonstrates a large malalignment VSD beneath the aortic valve and an overriding aorta (Fig. 19-55; see Figs. 19-37 and 19-38).^{180,181} The pulmonary valve appears small and thickened (see Fig. 19-38) in all but the mildest cases, and the main and branch pulmonary arteries typically appear somewhat hypoplastic.

Patients with TOF with pulmonary stenosis may or may not require any neonatal intervention. After postnatal confirmation of the diagnosis, those with mild pulmonary stenosis may be discharged home without neonatal surgery or medical treatment, with definitive repair planned for sometime during the first year of life. Those with more severe pulmonary stenosis will require earlier surgical intervention, either primary intracardiac repair (reconstruction of the RVOT and closure of the VSD) or early placement of an aortopulmonary shunt

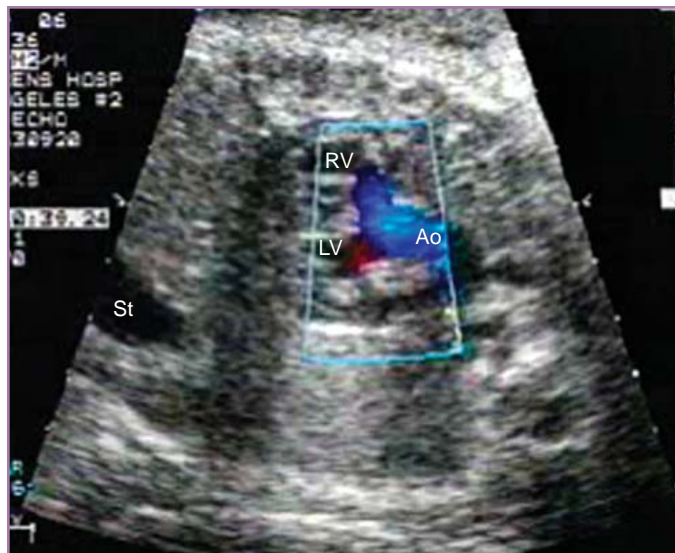


FIGURE 19-55 Fetal echocardiographic image of tetralogy of Fallot demonstrated in left ventricular long-axis view. Compare with Figure 19-37. Color flow demonstrates right-to-left shunting across the malalignment ventricular septal defect. Ao, aorta; LV, left ventricle; RV, right ventricle; St, fetal stomach.

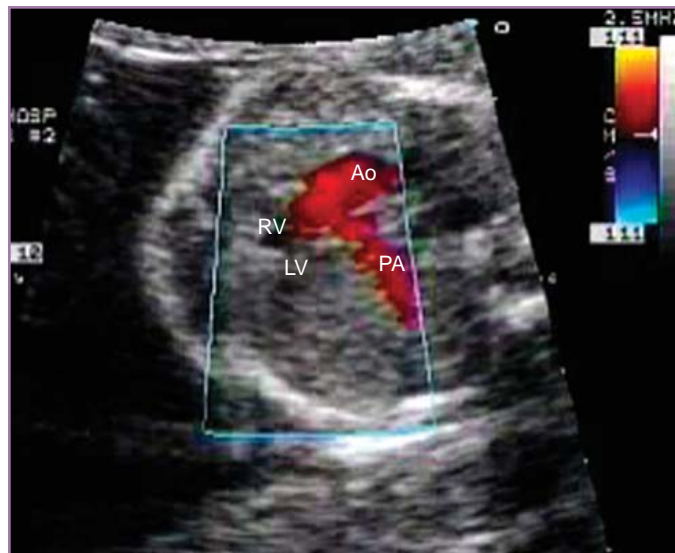

FIGURE 19-56 Fetal echocardiographic image of tetralogy of Fallot with pulmonary atresia. Color flow imaging demonstrates retrograde flow into the pulmonary artery, helping to distinguish this lesion from truncus arteriosus. Ao, aorta; LV, left ventricle; PA, pulmonary artery; RV, right ventricle.

(to augment pulmonary blood flow) followed by intracardiac repair later during the first year. The outlook for these patients is generally excellent,¹⁸⁰ although those with more severely affected pulmonary valves may require multiple pulmonary valve replacements over a lifetime.

Tetralogy of Fallot with Pulmonary Atresia

In TOF/PA the lungs receive their blood supply either from retrograde flow through the ductus arteriosus or through multiple aortopulmonary collaterals arising from various points along the aortic arch. Patients with ductal-dependent pulmonary blood flow usually have well-formed pulmonary arteries; their long-term prognosis is excellent and is comparable to that of patients with TOF and severe pulmonary stenosis. In contrast, patients with pulmonary blood flow dependent on aortopulmonary collaterals usually have severely hypoplastic or absent true pulmonary arteries and face a much more guarded long-term prognosis.

TOF/PA, like TOF with pulmonary stenosis, typically exhibits a normal 4CV prenatally. Evaluation of the outflow tracts demonstrates an atretic pulmonary valve and, often, absence of the main pulmonary artery.¹⁸¹ Patients with ductal-dependent pulmonary blood flow have a large, tortuous ductus arteriosus flowing into hypoplastic but relatively well-formed branch pulmonary arteries (Fig. 19-56). In contrast, patients with collateral-dependent pulmonary blood flow have severely hypoplastic or absent pulmonary arteries, an absent ductus arteriosus, and multiple aortopulmonary collaterals visible with color flow imaging of the aortic arch.¹⁴⁴

After delivery, some patients with TOF/PA may require cardiac catheterization to visualize the source of pulmonary blood flow. Patients with ductal-dependent pulmonary blood flow may undergo neonatal placement of an aortopulmonary shunt. Those patients with collateral-dependent pulmonary blood flow face a far more complicated course, requiring case-specific medical and surgical management, and a much more guarded prognosis.

Tetralogy of Fallot with Absent Pulmonary Valve

TOF/APV represents an unusual lesion with risks for both cardiac and pulmonary complications. In TOF/APV, primitive, donut-shaped pulmonary valve tissue causes both pulmonary stenosis and pulmonary regurgitation. As a result, the right ventricle and tricuspid valve annulus dilate, frequently causing tricuspid regurgitation and the potential for CHF, even during fetal life. Typically, the ductus arteriosus is absent, even during fetal life. The combination of an augmented right ventricular stroke volume and absent ductus arteriosus causes the branch pulmonary arteries to dilate aneurysmally. As a result, patients with TOF/APV may be born with pulmonary hypoplasia or severe airway disease, or both, related to chronic extrinsic compression by markedly dilated pulmonary arteries during fetal life.

Unlike simple forms of TOF, TOF/APV manifests typically during fetal life with both an abnormal 4CV and abnormal outflow tracts.¹⁸²⁻¹⁸⁴ Because of the pulmonary regurgitation, the right ventricle typically appears dilated. With significant stretch of the tricuspid valve annulus, tricuspid regurgitation may cause right atrial enlargement. In addition, elevated right ventricular diastolic pressure contributes to right atrial enlargement. Scanning into the LVOT demonstrates the malalignment VSD and overriding aorta. Angulation toward the RVOT demonstrates a small, donut-like pulmonary valve annulus, with pulmonary stenosis and regurgitation seen with color flow imaging. Probably the most recognizable features of TOF/APV are its aneurysmally dilated branch pulmonary arteries (Fig. 19-57), which may resemble “Mickey Mouse” ears and may appear to pulsate.

After delivery, many newborns with TOF/APV suffer from pulmonary hypoplasia or severe airway disease. This type of presentation carries a poor prognosis. Many infants without respiratory compromise have a good long-term prognosis,¹⁸²⁻¹⁸⁴ albeit with multiple pulmonary valve replacements during a lifetime. Because patients with TOF/APV typically do not have a ductus arteriosus, prostaglandin

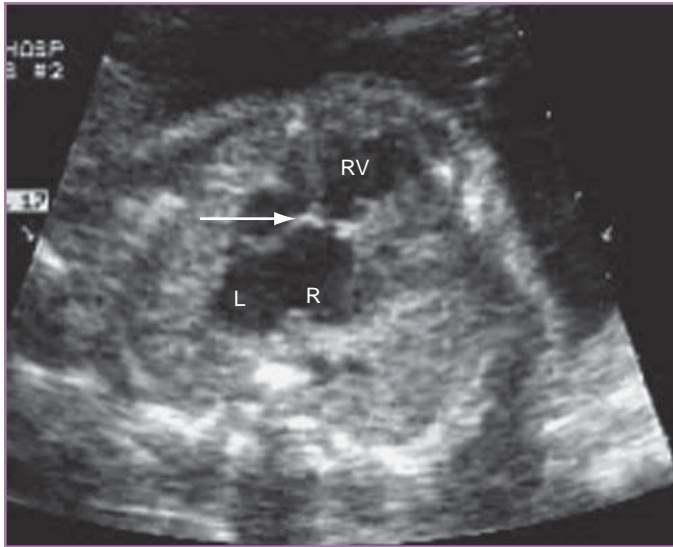


FIGURE 19-57 Fetal echocardiographic image of tetralogy of Fallot with absent pulmonary valve. Primitive tissue at the level of the pulmonary annulus (*arrow*) allows for both pulmonary stenosis and pulmonary regurgitation, which in turn leads to aneurysmal dilation of the branch pulmonary arteries and dilation of the right ventricle. L, left pulmonary artery; R, right pulmonary artery; RV, right ventricle.

generally has little benefit during the neonatal period. Those infants without respiratory compromise need detailed echocardiographic and clinical evaluation to determine the appropriate timing for surgical intervention.

Double-outlet Right Ventricle

DORV represents a heterogeneous group of congenital heart defects that have in common the origin of both great arteries from the right ventricle. Technically, DORV also implies mitral-aortic discontinuity, with conal tissue beneath both great arteries. Because of varying size and location of the VSD, as well as variable degrees of pulmonary stenosis, infants with DORV may present with the pathophysiology of TOF, TGA, VSD, or single ventricle. DORV also commonly occurs in conjunction with other structural defects.¹⁸⁵ Neonatal management and prognosis vary accordingly.

Although some cases of DORV exhibit a large VSD or ventricular asymmetry on the 4CV, virtually all fetuses with DORV have abnormalities of the outflow tracts.¹⁸⁰ The left ventricular long-axis view does not demonstrate the aorta arising from the left ventricle. Instead, the aorta is seen to arise entirely or in part from the right ventricle. The pulmonary artery similarly arises entirely or in part from the right ventricle. If either great artery arises partially from the left and partially from the right ventricle, a VSD will be seen immediately beneath the straddling great artery. In addition, in DORV, the relative spatial relationship between the aortic and pulmonary valves may vary considerably. The great arteries in DORV commonly, but not always, lack the normal crossing seen in hearts with normally related great arteries. Finally, DORV typically manifests with pulmonary stenosis, and rarely with aortic stenosis. As with other cardiac lesions, pulmonary stenosis commonly coexists with pulmonary artery hypoplasia, and aortic stenosis commonly coexists with aortic arch hypoplasia and coarctation of the aorta.

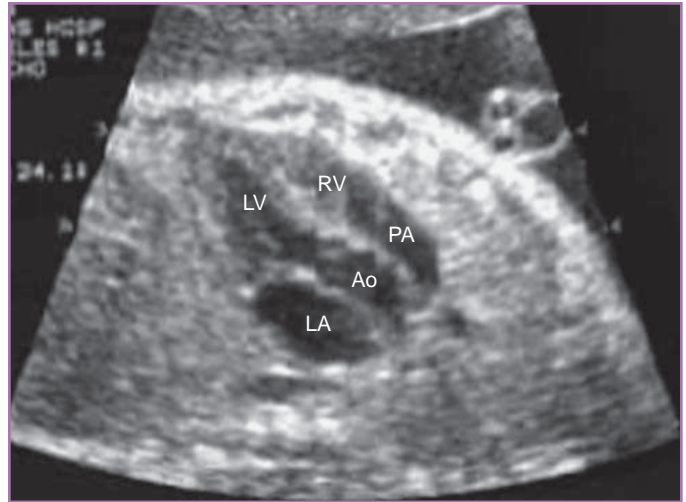


FIGURE 19-58 Fetal echocardiographic image of transposition of the great arteries. Note the absence of crossing of the great arteries. Ao, aorta; LA, left atrium; LV, left ventricle; PA, pulmonary artery; RV, right ventricle.

The approach to management of DORV in the neonate requires detailed clinical and echocardiographic evaluation after delivery, because details of the anatomy and pathophysiology dictate the medical and surgical approach. Prognosis varies from that of mild TOF (excellent) to that of HLHS with hypoplastic pulmonary arteries (very poor).¹⁸⁰

Transposition of the Great Arteries

In TGA, the aorta arises from the right ventricle, and the pulmonary artery arises from the left ventricle. Management and prognosis vary widely, depending on details of the anatomy and pathophysiology. Two major types of TGA have been described: dextro- or D-TGA and levo- or L-TGA. These are discussed separately.

D-TGA

Generally, D-TGA refers to TGA in which the visceral situs is normal (stomach on the left and liver on the right) and the ventricular looping is normal (D-looped). In D-TGA, the aortic valve is typically anterior and rightward of the pulmonary valve. As a result, systemic venous return passes from right atrium to right ventricle to aorta, and pulmonary venous return passes from left atrium to left ventricle to pulmonary artery. The patient with D-TGA may or may not have a VSD, other cardiac abnormalities, or heterotaxy.^{110,157}

The fetus with isolated D-TGA usually has an entirely normal 4CV but markedly abnormal views of the outflow tracts.¹⁸⁰ Any restriction to flow at the level of the foramen ovale should be noted with spectral and color flow Doppler evaluations,^{18,186} because newborns with restricted interatrial communications may require emergent balloon atrial septostomies, something not available at most hospitals. Unlike normally related great arteries, the great arteries in D-TGA do not cross each other (Fig. 19-58; see Fig. 19-39). Instead, the pulmonary artery arises from the left ventricle and heads posteriorly, and the aorta arises from the right ventricle and heads superiorly to give off the head and neck vessels before joining the descending aorta at the isthmus. In addition, in D-TGA, the pulmonary valve and main pulmonary artery (both arising from the left ventricle) should appear slightly larger than

the aortic valve and aortic root (both arising from the right ventricle). The ductus arteriosus should be evaluated with 2D imaging and color/spectral Doppler for evidence of ductal constriction.^{18,186}

The newborn with D-TGA usually is dependent on the ductus arteriosus for adequate oxygenation. In addition, unless a large VSD is present, oxygenation relies on a large atrial communication. As a result, patients with D-TGA usually require prostaglandin infusion and may require balloon atrial septostomy relatively emergently after delivery. Subsequently, patients with straightforward D-TGA usually undergo the arterial switch operation within the first 1 to 2 weeks after delivery. The prognosis can be excellent but depends largely on associated cardiac (see Fig. 19-39) and extracardiac abnormalities.¹⁸⁰

L-TGA

The term L-TGA describes the heart with normal visceral situs, L-looped ventricles, and TGA. Usually, in L-TGA, the aortic valve sits anterior and leftward of the pulmonary valve. In L-TGA, the systemic venous return passes from right atrium to left ventricle to pulmonary artery, and the pulmonary venous return passes from left atrium to right ventricle to aorta. For this reason, L-TGA has been described as “congenitally corrected transposition.” In many cases, however, L-TGA occurs in conjunction with a VSD, Ebstein anomaly of the left-sided tricuspid valve, heart block, pulmonary stenosis/atresia, or some combination of these. Such associated abnormalities affect the prenatal and postnatal presentation, management, and prognosis.

Typically, L-TGA manifests in the fetus with both an abnormal 4CV and abnormal outflow tracts.^{187,188} L-looped ventricles are present on the 4CV, with a left ventricle anterior and rightward of a posterior and leftward right ventricle (Fig. 19-59). The right ventricle can be distinguished from the left ventricle by the presence of coarse trabeculations

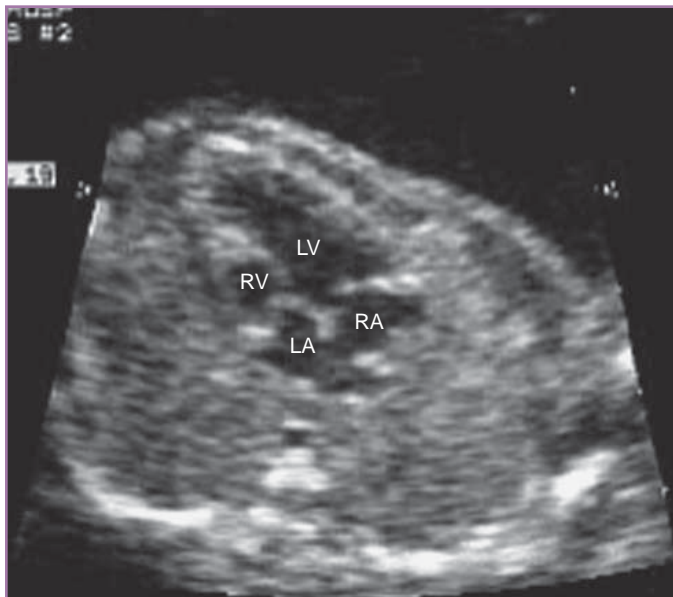


FIGURE 19-59 Fetal echocardiographic image of the four-chamber view demonstrating congenitally corrected transposition of the great arteries. Note the presence of a smooth-walled left ventricle anteriorly and rightward and a more trabeculated right ventricle posteriorly and leftward. The tricuspid valve, associated with the right ventricle, inserts more apically onto the ventricular septum than does the right-sided mitral valve. LA, left atrium; LV, left ventricle; RA, right atrium; RV, right ventricle.

and moderator band, and by a tricuspid valve that inserts onto the ventricular septum slightly more apically than the left ventricle’s mitral valve. In addition, those fetuses with associated Ebstein anomaly of the tricuspid valve, which is always associated with the right ventricle, have that lesion’s characteristic findings (but with left atrial rather than right atrial dilation). Imaging of the outflow tracts demonstrates absence of crossing of one outflow over the other. The aortic valve, arising anterior and leftward of the pulmonary valve, gives rise to the aorta, which heads superiorly. In contrast, the pulmonary valve, arising posterior and rightward of the aortic valve, gives rise to the pulmonary artery, which heads posteriorly. Pulmonary stenosis or atresia is detectable with 2D and color flow imaging and may affect the development of the main and branch pulmonary arteries. The presence of a VSD may be seen on either the 4CV or outflow tract views, depending on the size and location of the VSD: The more anterior the VSD, the more likely it is to be seen with imaging of the outflow tracts, and the less likely to be seen on the 4CV. Finally, heart block may develop at any time prenatally or after birth and may be documented with 2D imaging, spectral Doppler, or M-mode evaluation (see later discussion).

After delivery, patients with straightforward L-TGA may not require any intervention, even for many years. However, the presence of any associated abnormalities may require neonatal or subsequent medical or surgical intervention. All patients require close clinical, echocardiographic, and electrocardiographic evaluation postnatally. Long-term prognosis varies widely, but, without surgery, all patients remain at risk for heart failure and arrhythmias because of their systemic right ventricle.^{187,188}

Truncus Arteriosus

Truncus arteriosus represents a complex conotruncal malformation wherein a single arterial trunk arises from the heart and gives rise to the systemic, pulmonary, and coronary circulations. Truncus arteriosus arises from abnormal development of the truncal ridges and aortopulmonary septum and carries a strong association with DiGeorge syndrome.²³ Most cases have no ductus arteriosus during fetal life, except in the rare form associated with interrupted aortic arch.

Prenatally, truncus arteriosus exhibits a normal 4CV but markedly abnormal outflow tract views.^{180,189,190} The truncal valve commonly appears mildly thickened, overrides a large VSD, and may have some degree of regurgitation on color flow imaging. The pulmonary arteries arise from the truncal root either as a common main pulmonary artery (Fig. 19-60) or as separate origins of right and left branch pulmonary arteries. It can be difficult to differentiate truncus arteriosus from TOF/PA prenatally. Both lesions show a single semilunar valve overriding a VSD. Both lesions have a normal 4CV, and both have strong associations with DiGeorge syndrome.²³ The distinction may be made, however, by assessing the direction of blood flow within the pulmonary arteries. In the case of TOF/PA, blood flow in the pulmonary arteries is retrograde from the ductus arteriosus (see Fig. 19-56), or it may not be seen at all in the case of collateral-dependent pulmonary blood flow. In truncus arteriosus, blood from the pulmonary arteries is prograde from the truncal root. In addition, whereas the aortic valve in TOF/PA usually appears large but thin and delicate, the truncal valve in truncus arteriosus typically appears somewhat thickened, eccentric, and, occasionally, regurgitant.

After delivery, all patients require close clinical and echocardiographic evaluation, as well as evaluation for DiGeorge syndrome. Commonly, patients with truncus arteriosus undergo surgical repair within the first few weeks after delivery, with VSD closure and placement of a pulmonary homograft into the RVOT. As with TOF/PA, the

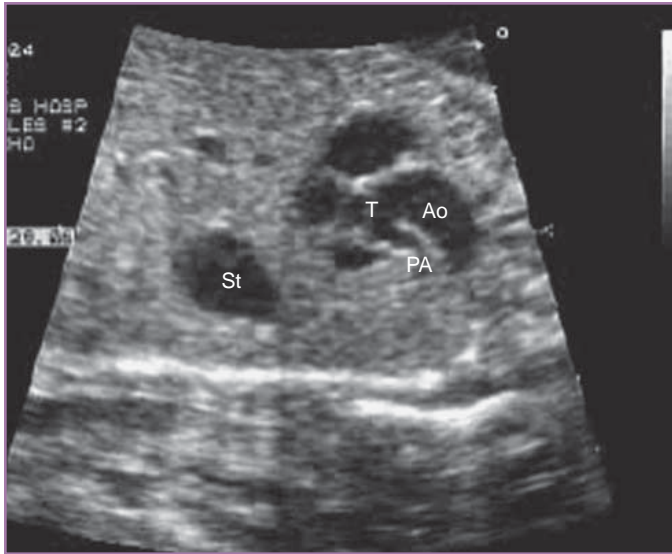


FIGURE 19-60 Fetal echocardiographic sagittal image of truncus arteriosus. The pulmonary artery arises from the proximal truncal root. Ao, aorta; PA, pulmonary artery; St, stomach; T, truncal root.

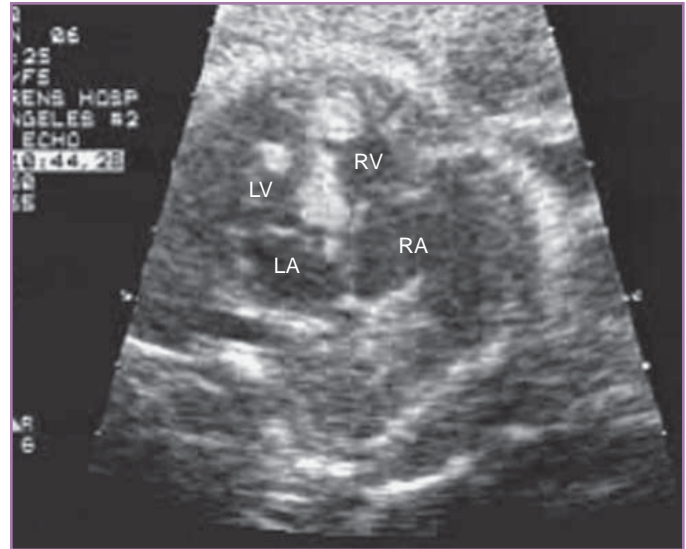


FIGURE 19-61 Fetal echocardiographic image of four-chamber view demonstrating multiple ventricular rhabdomyomas. LA, left atrium; LV, left ventricle; RA, right atrium; RV, right ventricle.

pulmonary homograft will require multiple replacements during a lifetime. Long-term prognosis depends on the associated abnormalities and truncal valve function but can be quite good if all goes well.^{189,190}

Cardiac Tumors

Fetal cardiac tumors, although rarely malignant in the oncologic sense, may be life-threatening in their own right or may be associated with systemic syndromes. This section reviews two of the most common cardiac tumors seen in the fetus: rhabdomyoma and intrapericardial teratoma. Both appear to have their greatest period of growth from mid-gestation to term. Readers may consult other sources for more detailed discussions of fetal cardiac tumors.^{8,9,152,153,191,192}

Cardiac Rhabdomyoma

By far the most common fetal cardiac tumor,^{191,192} cardiac rhabdomyoma may occur as an isolated, single cardiac mass or, more commonly, as a collection of well-circumscribed tumors. In a substantial percentage of cases, cardiac rhabdomyomas occur as one manifestation of tuberous sclerosis.^{193,194} Although tuberous sclerosis may be associated with significant neurologic disease, including seizures, developmental delay, and cognitive impairment,²³ cardiac rhabdomyomas often do not cause cardiovascular pathology, either prenatally or after delivery. Occasionally, however, cardiac rhabdomyomas may become obstructive to flow in or out of one or both ventricles, may adversely affect myocardial function, may generate atrial or ventricular arrhythmias, and may be associated with WPW syndrome. In the absence of fetal arrhythmias, diminished ventricular function, obstruction to flow, or CHF, the fetus with cardiac rhabdomyomas rarely will develop cardiovascular pathology postnatally, short of SVT in the presence of WPW. In fact, cardiac rhabdomyomas typically regress or remain stable in size postnatally,^{193,194} in contrast to other tumors, which may grow substantially after delivery.

The diagnosis of cardiac rhabdomyomas can generally be made from a 4CV. Most cardiac rhabdomyomas manifest as echogenic, homogeneous, well-circumscribed masses within or extending par-

tially into the ventricular free wall or ventricular septum or both (Fig. 19-61). Rarely, cardiac rhabdomyomas reside predominantly within the walls of the right or left atrium. In contrast, benign echogenic reflectors or foci reside exclusively within the chordal apparatus of the mitral or tricuspid valves and do not extend into the ventricular myocardium.

The fetus with suspected cardiac rhabdomyomas should be evaluated thoroughly for tuberous sclerosis, possibly including sonography, magnetic resonance imaging, and/or genetic means of analysis. After delivery, affected infants should again undergo comprehensive evaluation for tuberous sclerosis, a repeat echocardiographic evaluation, and an electrocardiogram to assess for WPW. Long-term prognosis, from a cardiovascular standpoint, is excellent if no significant rhythm, ventricular dysfunction, or hemodynamic obstruction manifests during the late fetal or neonatal periods.

Intrapericardial Teratoma

The intrapericardial teratoma is probably the second most common primary fetal cardiac tumor. Like the cardiac rhabdomyoma, it may be considered benign in the oncologic sense,^{8,152,191,192} but affected fetuses may develop CHF or hydrops secondary to progressive enlargement of the pericardial effusion. Histologically, the intrapericardial teratoma represents a combination of cystic areas, lined by various forms of epithelium, surrounded by solid areas composed of muscle, nerve, pancreas, cartilage, thyroid, or bone tissues. Intrapericardial teratomas typically arise from the ascending aorta and secrete fluid into the pericardial space. Over time, the expanding pericardial effusion can impede cardiac output, and the resultant tamponade physiology can result in fetal demise. After delivery, mass effect of the tumor may impede cardiac output or cause respiratory compromise by compressing the trachea or mainstem bronchi.¹⁹⁵

The diagnosis of intrapericardial teratoma may be suspected in the fetus with a pericardial effusion in conjunction with a heterogeneous, cystic mass with areas of calcification that arises from the ascending aorta (Fig. 19-62). After the diagnosis is made, affected fetuses require close observation and may benefit from pericardiocentesis for progres-

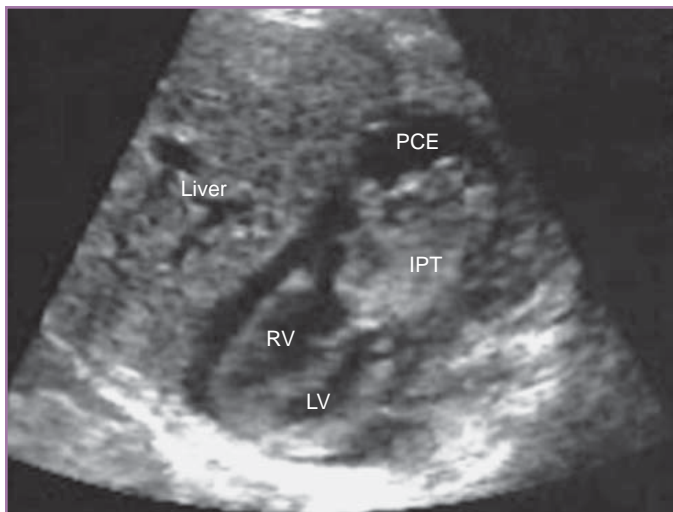


FIGURE 19-62 Fetal echocardiographic image of intrapericardial teratoma arising from the ascending aorta. Note the heterogeneous appearance of the tumor. IPT, intrapericardial teratoma; LV, left ventricle; PCE, pericardial effusion; RV, right ventricle.

TABLE 19-7 FETAL ARRHYTHMIAS

Irregular Rhythm

Premature atrial contractions/couplets
Second-degree heart block

Sustained Bradycardia

Sinus bradycardia
Atrial bradycardia
Blocked atrial bigeminy
Atrial flutter with high-degree block
Complete heart block

Sustained Tachycardia

Sinus tachycardia
Supraventricular tachycardia
Atrial flutter
Ventricular tachycardia

sive enlargement of the pericardial effusion and worsening tamponade.¹⁹⁵ Delivery should be arranged to allow for rapid intubation, if necessary, and subsequent early surgical resection of the tumor. Long-term prognosis after expeditious, early resection is excellent, with little chance for recurrence.

Fetal Arrhythmias: Diagnosis, Management, and Prognosis

This section reviews the diagnosis, management, and prognosis of the most common and important fetal arrhythmias (Table 19-7), with a distinctively clinical approach. For more detailed discussions of fetal arrhythmias, readers may refer to other, more comprehensive reviews.^{8,9,152,196-198}

Beyond demonstrating a normal transverse abdominal view, 4CV, and standard views of the outflow tracts, the normal fetal screening

TABLE 19-8 ANTIARRHYTHMIC MEDICATIONS FOR FETAL ARRHYTHMIAS

Fetal Arrhythmia	Potential Treatments*
Premature atrial/ventricular contractions	None
Atrial bigeminy (blocked or conducted)	None
Nonsustained SVT	Usually none (see text)
Sustained SVT	Digoxin Flecainide Amiodarone Propranolol
Atrial flutter	Digoxin Sotalol Propranolol Amiodarone
Ventricular tachycardia	Propranolol Sotalol Mexiletine Amiodarone
First/second/third-degree heart block (positive antibodies)	Dexamethasone?

*Note that all antiarrhythmic medications have the potential for serious, possibly fatal maternal and/or fetal proarrhythmia. Treatment of a specific fetus for an arrhythmia should be done only after careful consideration of anticipated benefits and potential risks and after full disclosure has been made to the mother.
SVT, supraventricular tachycardia.

ultrasound evaluation should demonstrate physiologic rate and variability of the fetal heartbeat. The fetal heart rate should be physiologic (120 to 160 beats/min) and should have physiologic variability (small but real changes in heart rate during scanning, with prolonged or severe bradycardia only during periods of deep transducer pressure). Abnormal variability (irregular beats or extrasystoles) and abnormalities in rate (sustained bradycardia or tachycardia) should be noted, evaluated, and, if appropriate, treated. Most fetal arrhythmias are benign, are self-resolving, and do not require treatment.¹⁹⁶⁻¹⁹⁸ Treatment of a fetus for arrhythmia should be undertaken only after careful weighing of desired benefits against potential maternal and fetal complications and after full disclosure to the mother. Table 19-8 lists some of the most common antiarrhythmic medications used to treat fetal arrhythmias.

Premature Atrial Contractions

Premature atrial contractions (PACs), the most common fetal arrhythmia,¹⁹⁶⁻¹⁹⁹ manifest as an irregularly irregular variability in fetal heart rate, usually beginning between 18 and 24 weeks' gestation, but occasionally appearing initially during the third trimester. The diagnosis of PACs typically is made empirically by observing the rhythm with 2D imaging. However, to confirm the diagnosis, spectral Doppler inflow and outflow evaluation of the left ventricle or M-mode analysis should be performed.

Normally, by orienting the ultrasound beam in parallel with both left ventricular inflow and outflow (Fig. 19-63), spectral Doppler evaluation of sinus rhythm will demonstrate a biphasic inflow pattern for every atrial contraction (i.e., early passive filling followed by atrial contraction) and a single, uniphasic outflow pattern after each ventricular contraction (Fig. 19-64).^{200,201} PACs, by definition, come early, and they typically lack the early passive filling component (E wave) of the Doppler waveform (Fig. 19-65). Alternatively, M-mode

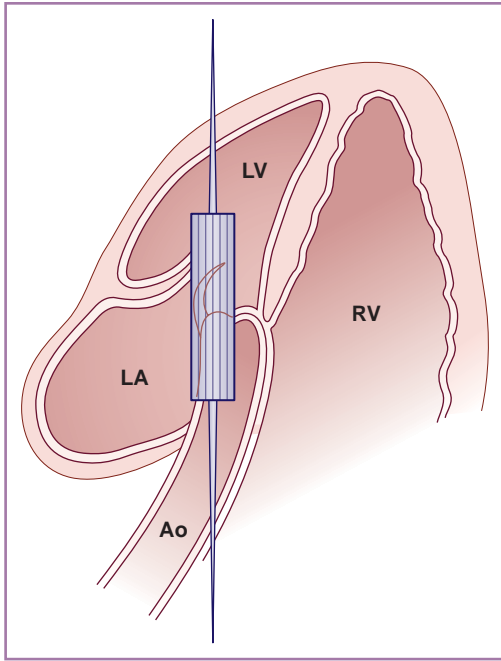


FIGURE 19-63 Schematic diagram of left ventricular inflow and outflow. The Doppler cursor is positioned in parallel with mitral and aortic flows to assist with the diagnosis of fetal arrhythmias. Ao, aorta; LA, left atrium; LV, left ventricle; RV, right ventricle. (Diagram courtesy of Irving R. Tessler, M.D.)

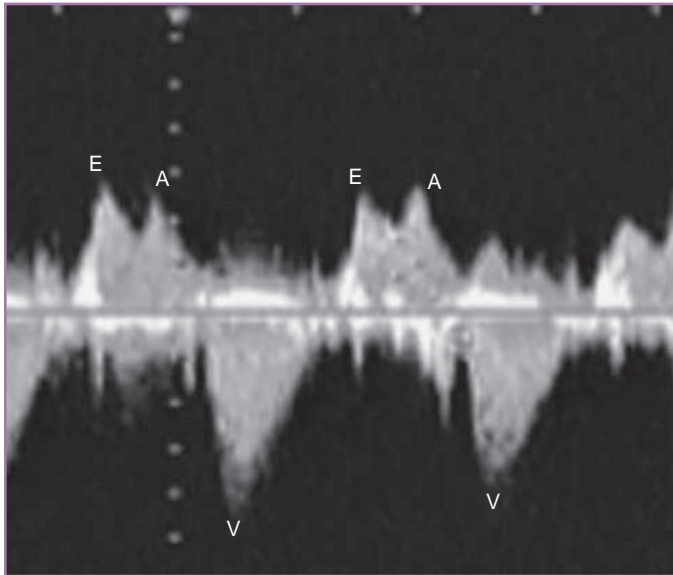


FIGURE 19-64 Fetal Doppler waveform obtained from left ventricular inflow and outflow demonstrating sinus rhythm. The Doppler cursor is positioned as in Figure 19-63. Note the biphasic mitral inflow, with passive early inflow (E wave) followed by atrial contraction (A wave). Each mitral inflow pattern is followed by single outflow. A, atrial contraction; E, early passive filling; V, ventricular contraction.

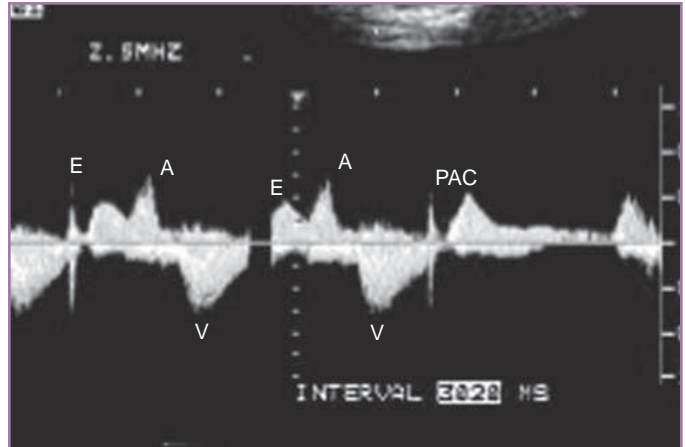


FIGURE 19-65 Fetal Doppler waveform obtained from left ventricular inflow and outflow demonstrating sinus rhythm with premature atrial contraction. The Doppler cursor is positioned as in Figure 19-63. The premature atrial contraction (PAC) comes early and is monophasic; it is blocked (i.e., not followed by ventricular contraction). A, atrial contraction; E, early passive filling; V, ventricular contraction.

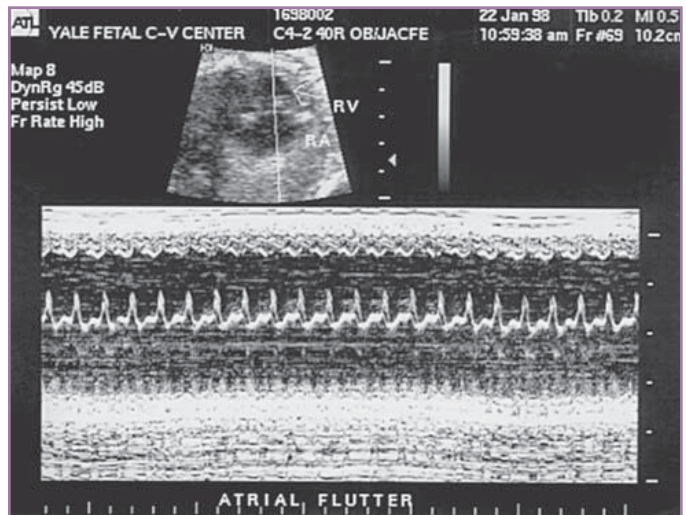


FIGURE 19-66 Fetal echocardiographic image of M-mode analysis of fetal arrhythmia. The M-mode cursor is placed across the right atrium and right ventricle (*inset*). This M-mode image demonstrates atrial flutter. (Image courtesy of Charles Kleinman, MD, Joshua Copel, MD, and Rodrigo Nehgme, MD.)

echocardiography allows visualization of atrial and ventricular contractions simultaneously when, guided by a 2D image, the M-mode sampling line is directed through the fetal atrium and ventricle (Fig. 19-66).²⁰² Other, more sophisticated approaches to evaluating fetal arrhythmias have also been developed.¹⁰¹

Rarely, PACs are associated with intermittent SVT. PACs may be exacerbated by ingestion of caffeine, decongestant medications (stimulants), or tobacco. Typically, PACs resolve spontaneously within 2 to 3 weeks after diagnosis. PACs do not represent any real risk to the fetus, and they do not require treatment. However, a small percentage of fetuses with isolated PACs develop SVT. Referral for further evaluation should be considered if concerns persist regarding the diagnosis or the possibility of additional arrhythmias or structural CHD.

Sustained Bradycardia

A sustained fetal heart rate of less than 120 beats/min represents fetal bradycardia and merits further evaluation. In contrast, fetal bradycardia related to deep transducer pressure or a particular maternal lie might represent a normal fetal response to stress. In such cases, if the fetal heart rate normalizes after relief of transducer pressure or change in maternal or fetal position, no further cardiac evaluation may be necessary.

The differential diagnosis of fetal bradycardia includes sinus bradycardia, atrial bradycardia, blocked atrial bigeminy, atrial flutter with high-degree block, and complete heart block. Treatment approaches and prognosis depend on the precise diagnosis. Sinus bradycardia, manifesting with a slow rate but with physiologic variability and with 1:1 conduction between the atria and ventricles, may represent fetal distress and therefore should prompt a thorough evaluation of fetal well-being and placental function. Particularly if it is associated with some degree of heart block, fetal sinus bradycardia may, rarely, be the first sign of long QT syndrome.²⁰³ Affected fetuses and newborns are at risk for ventricular tachycardia. For this reason, fetuses in good health that demonstrate unexplained sinus bradycardia without fetal distress should undergo electrocardiographic evaluation after delivery. In addition, because long QT syndrome may run in families, a family history for long QT syndrome, recurrent syncope, or sudden infant death syndrome should be sought. In contrast, atrial bradycardia may appear identical to sinus bradycardia, but it actually represents the normal rate of an accessory atrial pacemaker in the absence of an effective sinus node. Such an atrial bradycardia commonly occurs in conjunction with polysplenia, so the suspicion of this rhythm should prompt evaluation for the cardiac and abdominal abnormalities seen with polysplenia.^{106,110,157}

Occasionally, fetal sinus bradycardia represents blocked atrial bigeminy, in which normal sinus beats alternate with blocked PACs. In atrial bigeminy, the premature beats may be blocked if they occur very early, when the atrioventricular node is still refractory. In such cases, only sinus beats conduct, generating a uniform ventricular rate exactly half of the atrial rate. No specific therapy is warranted other than close observation and avoidance of caffeine, decongestant medications, and tobacco. Prognosis is excellent.

In some cases, atrial flutter may conduct consistently 3:1 or 4:1, and such fetuses may present with bradycardia. Close inspection of the heart with 2D imaging, M-mode, or spectral Doppler can diagnose the arrhythmia and assess the degree of conduction. Although atrial flutter usually has an atrial rate of 300 to 500 beats/min, high degrees of atrioventricular block may lead to fetal bradycardia; for example, atrial flutter with a flutter rate of 300 beats/min and a 3:1 conduction would present with a fetal ventricular rate of 100 beats/min. Unlike SVT, atrial flutter rarely manifests as intermittent tachycardia; flutter typically is incessant, although the ventricular response rate may vary. Like other fetal arrhythmias, fetal atrial flutter may be associated with structural heart disease. Treatment of atrial flutter, typically with maternal orally administered pharmacologic therapy (e.g., digoxin, sotalol, amiodarone) can slow the ventricular response rate and decrease the likelihood of development of fetal CHF or hydrops. Some investigators believe that sotalol has emerged as a potential first-line agent for the treatment of atrial flutter.²⁰⁴

Complete heart block (CHB) in the fetus typically manifests with a sustained fetal heart rate in the range of 40 to 70 beats/min (Fig. 19-67). In the fetus with complete heart block, the atrial rate remains normal but atrial contractions do not conduct to the ventricles. As a result, the ventricles depolarize with their own intrinsic rate. Approxi-

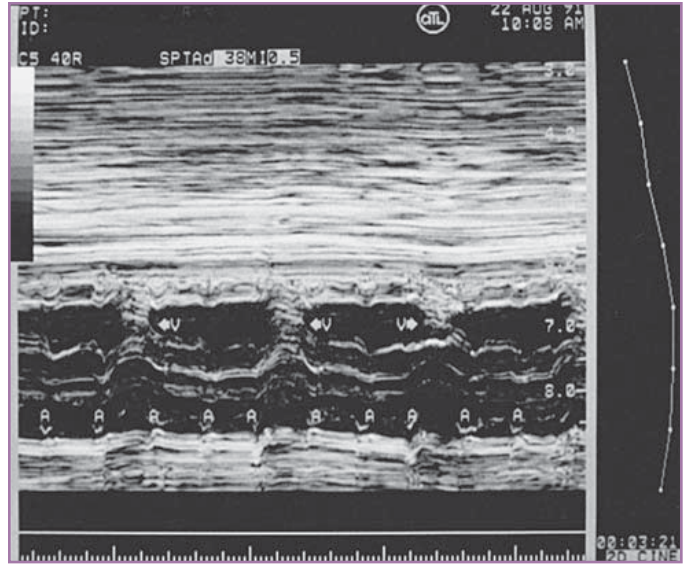


FIGURE 19-67 Fetal echocardiographic image of M-mode demonstration of complete heart block. A, atrial contraction; V, ventricular contraction. (Image courtesy of Charles Kleinman, MD, Joshua Copel, MD, and Rodrigo Nehgme, MD.)

mately 50% of cases of fetal complete heart block occur in the presence of structural heart disease (L-looped ventricles, atrioventricular septal defects, or complex forms of heart disease associated with polysplenia).^{157,196,205} These cases have a relatively poor prognosis, with a high rate of fetal demise related to progressive heart failure and hydrops. Therapy with maternal oral agents such as terbutaline or other sympathomimetics has not been shown to improve the outcome.

The other 50% of cases of fetal heart block occur secondary to damage to the fetal atrioventricular node by maternal anti-Ro and/or anti-La antibodies,²⁰⁵⁻²⁰⁷ usually in the context of maternal systemic lupus erythematosus, Sjögren's syndrome, or related connective tissue disorders. In some of these cases, maternal treatment with dexamethasone has improved fetal outcome, probably by improving myocardial function in the face of presumptive immune-mediated myocarditis.²⁰⁸⁻²¹⁰ Some investigators have used sympathomimetics agents to increase ventricular rates in this setting, particularly for rates that remain slower than 55 beats/min,²¹¹ but sustained increases in fetal heart rate have rarely been achieved. Pregnancies complicated by anti-Ro or anti-La antibodies carry a risk of approximately 1% for the development of fetal heart block,²¹² and the recurrence rate for a second fetus with heart block in antibody-positive pregnancies may be as high as 15%.²⁰⁷ Spectral Doppler evaluation of the fetal PR interval has been shown to be a useful way to identify fetuses in anti-Ro or anti-La antibody-positive pregnancies with evidence of atrioventricular node disease.^{213,214} Treatment of fetuses at risk (first-, second-, or third-degree heart block in antibody-positive pregnancies) with dexamethasone may prevent the progression to CHB or otherwise improve outcome by enhancing myocardial function, but such management remains controversial.^{208-210,215,216}

Sustained Tachycardia

SVT represents the great majority of instances of sustained fetal tachycardia. Sinus tachycardia represents an unusual response to fetal heart failure or distress. Fetal ventricular tachycardia occurs still far less commonly.

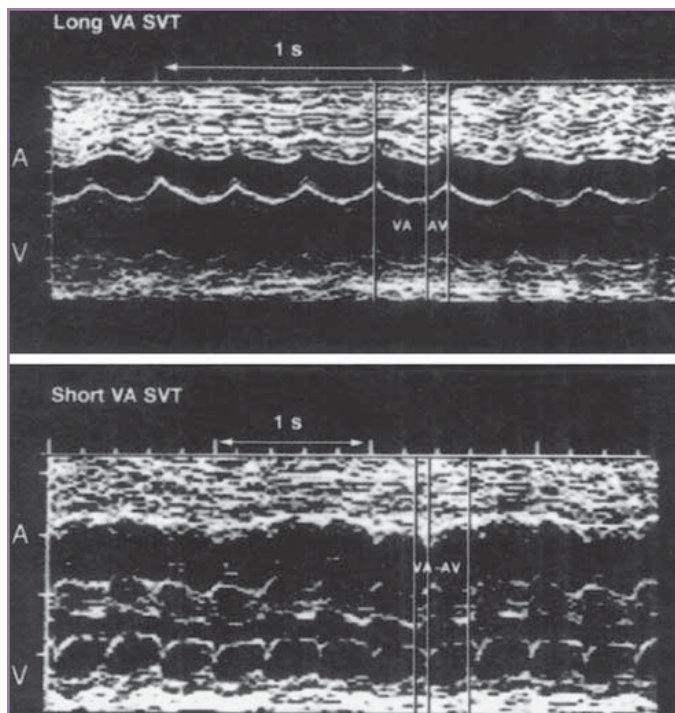


FIGURE 19-68 Fetal echocardiographic image of M-mode demonstration of two types of supraventricular tachycardia. In contrast to ventricular tachycardia, both types (i.e., long- and short-VA SVT) have 1:1 atrioventricular association. A, atrial contraction; AV, interval between atrial and ventricular contraction; SVT, supraventricular tachycardia; V, ventricular contraction; VA, interval between ventricular and atrial contraction. (Reproduced with permission from Jaeggi E, Fournon JC, Fournier A, et al: Ventriculo-atrial time interval measured on M-mode echocardiography: A determining element in diagnosis, treatment, and prognosis of fetal supraventricular tachycardia. *Heart* 79:582, 1998. Image courtesy of Charles Kleinman, MD, Joshua Copel, MD, and Rodrigo Nehgme, MD.)

Supraventricular Tachycardia

Fetal SVT typically occurs via an accessory pathway, although autonomic forms of fetal SVT also occur relatively commonly. Fetal SVT, usually in the range of 240 to 280 beats/min, occurs most frequently in fetuses with structurally normal hearts and rarely occurs in the setting of structural CHD. However, fetal SVT may be associated with WPW syndrome. The diagnosis of SVT may be suggested by 2D imaging, by spectral Doppler assessment of the left ventricular inflow and outflow tracts (see Fig. 19-63), or by M-mode analysis (Fig. 19-68). Ventricular tachycardia, which is typically slower but less well tolerated than SVT, may be associated with ventricular structural abnormalities or tumors or may occur in the context of long QT interval. Ventricular tachycardia can be difficult to discriminate from fetal SVT, even with M-mode or spectral Doppler analysis,^{196,197,217} although ventricular tachycardia is typically far less well tolerated. Because fetal SVT typically manifests as an intermittent, nonsustained arrhythmia, the presence of PACs or atrial couplets can help strengthen the certainty of the diagnosis. Moreover, unlike ventricular tachycardia, SVT usually conducts 1:1 from atria to ventricles.

Although few would dispute treatment of fetal SVT in the face of hydrops and in the absence of lung maturity, no consensus exists on

the approach to the second-trimester (or early third-trimester) fetus with SVT in the absence of hydrops.^{196,197,217-219} As would be expected, SVT in a fetus with structural heart disease is far less well tolerated than SVT in one with a structurally normal heart. However, therapeutic strategies advocated for the nonhydropic, immature fetus with SVT remain largely divergent, ranging from treatment of any documented SVT to treatment only with the development of hydrops.²¹⁷ No consensus has been reached on the exact relationship between heart rate, type of SVT, and development of hydrops in the context of fetal SVT. Antiarrhythmic agents, dosing schedules, and routes of administration represent separate areas of controversy and disagreement, similarly without consensus.

Although each case may be handled somewhat differently, depending on patient characteristics and physician biases, the following represents our institution's approach. The presence of structural heart disease in the context of SVT lowers the tolerance for shortened diastolic filling times and elevated central venous pressure, so such fetuses typically receive treatment earlier than do fetuses with structurally normal hearts. When fetal SVT becomes complicated by hydrops, the threshold for treatment falls much further. In the absence of fetal structural heart disease or hydrops, fetal SVT usually receives treatment if the tachycardia occurs more than 33% of the time. However, beyond 32 to 34 weeks' gestation, many cases of fetal tachycardia may be better approached with delivery than with maternally administered medications, all of which have variable efficacy and carry the potential for both maternal and fetal toxicity. Before treatment, all potential precipitating factors (tobacco, decongestant medications, and caffeine) are withdrawn, and the fetal rhythm is monitored in-house for 8 to 24 hours to assess the percentage of time during which the fetus is in tachycardia. The mother is informed of all possible fetal and maternal risks to therapy, as well as the anticipated benefit to treatment. All antiarrhythmic agents have the potential for maternal and/or fetal proarrhythmia. Because maternal serum factors rarely may react with assays for digoxin,²²⁰ a maternal serum digoxin level is determined, along with a set of electrolytes and creatinine. A maternal electrocardiogram and, ideally, consultation with an adult cardiologist is performed before therapy is initiated. The presence of WPW or other abnormality on the maternal electrocardiogram may contraindicate the use of certain forms of antiarrhythmic therapy (e.g., digoxin).

When indicated, and only in the absence of any contraindication, treatment may begin with a digoxin load, using 0.5 mg intravenously every 6 to 8 hours, with a maternal serum digoxin measurement and electrocardiogram performed before each dose. Loading continues until effect (<25% tachycardia or decreased hydrops or both), therapeutic level (2.0 µg/mL), maternal toxicity (maternal symptoms or electrocardiographic abnormalities beyond first-degree heart block), or fetal toxicity (worsening of arrhythmia) is reached, whichever comes first. After a desired effect has been safely achieved, digoxin is administered orally two to four times daily, usually at 0.25 to 0.5 mg per dose. Often, consultation with the hospital pharmacologist is useful. Patients are discharged after a steady state has been achieved with acceptable control of the fetal arrhythmia, acceptable maternal serum digoxin levels, and absence of maternal or fetal toxicity. However, close outpatient follow-up is essential to confirm continued effect and lack of toxicity, and occasionally to increase dosing as maternal volumes of distribution continue to increase during the second and third trimesters. If digoxin fails to achieve adequate control, second-line agents such as propranolol,^{196,197} flecainide,²²¹ or amiodarone²²² may be substituted or added, but the potential for toxicity increases and the likelihood for efficacy decreases.^{196,197}

Atrial Flutter

In contrast to fetal SVT, fetal atrial flutter ranges between 300 and 500 atrial contractions per minute, with a ventricular rate that may vary from less than 100 to more than 300 beats/min.^{196,197,223} In atrial flutter, the atrioventricular node refractory periods may vary, occasionally producing 1:1 conduction but more typically allowing only every second or third atrial contraction to conduct to the ventricles (2:1 or 3:1 conduction, respectively) (see Fig. 19-66). Flutter usually manifests in a much more sustained fashion than does SVT, which commonly produces intermittent runs of tachycardia interspersed with periods of sinus rhythm. Compared with SVT, atrial flutter has a higher association with structural heart disease, although structural heart disease is still rare in the neonate with atrial flutter.²²⁴ Finally, although flutter may be successfully treated with maternally administered digoxin, recent reports suggest that sotalol is an excellent second-line agent, and some centers have chosen sotalol as their first-line therapy for fetal atrial flutter.²⁰⁴ Propranolol has also been used successfully to control the ventricular response rate in the fetus with atrial flutter.¹⁹⁷

Ventricular Tachycardia

Ventricular tachycardia in the fetus, as in newborns and children, represents a commonly fatal arrhythmia when sustained. In part for this reason, fetal ventricular tachycardia is diagnosed far less often than fetal SVT, although fetal ventricular tachycardia is also far less common than fetal SVT. Fetal ventricular tachycardia usually manifests with fetal rates between 180 and 300 beats/min and, often, poor ventricular function. Discrimination of ventricular tachycardia from SVT can be challenging but is important, because digoxin is contraindicated for ventricular tachycardia. Unlike SVT, ventricular tachycardia has dissociation between atrial and ventricular contractions (Fig. 19-69). Ventricular tachycardia that is associated with structural heart disease carries a particularly poor prognosis. Fetal ventricular tachycardia has been associated with tumors (usually rhabdomyomas), structural heart disease (cardiomyopathy, severe right or left ventricular hypertrophy or coronary abnormalities), prolonged QT interval,²⁰³ and fetal distress or acidosis. Lower ventricular rates (180 to 220 beats/min) may be

better tolerated, with improved outcomes compared with higher ventricular rates. In some cases, treatment may be attempted with lidocaine (administered directly into the fetal umbilical vein) or with oral maternal administration of propranolol, mexiletine, sotalol, or amiodarone, but the prognosis remains guarded.^{196,197,222}

Conclusions

The detection, diagnosis, and management of fetal structural heart defects and arrhythmias remain important challenges for those involved in fetal screening ultrasonography or detailed evaluation of the fetal heart. The assessment and management of the fetal heart, in both low-risk and high-risk pregnancies, requires attention to detail, experience, and a collaborative effort among multiple specialists caring for the fetal patient.

References

- Allan L, Benacerraf B, Copel J, et al: Isolated major congenital heart disease. *Ultrasound Obstet Gynecol* 17:370, 2001.
- International Society of Ultrasound in Obstetrics and Gynecology: Cardiac screening examination of the fetus: Guidelines for performing the "basic" and "extended basic" cardiac scan. *Ultrasound Obstet Gynecol* 27:107, 2006.
- Tegnander E, Eik-Nes S: The examiner's ultrasound experience has a significant impact on the detection rate of congenital heart defects at the second-trimester fetal examination. *Ultrasound Obstet Gynecol* 28:8, 2006.
- Chaoui R: The four-chamber view: Four reasons why it seems to fail in screening for cardiac abnormalities and suggestions to improve detection rates. *Ultrasound Obstet Gynecol* 22:3, 2003.
- Jaggi E, Sholler G, Jones O, et al: Comparative analysis of pattern, management and outcome or pre- versus postnatally diagnosed major congenital heart disease: A population-based study. *Ultrasound Obstet Gynecol* 17:380, 2001.
- Garne E, Stoll C, Clementi M; Euroscan Group: Evaluation of prenatal diagnosis of congenital heart diseases by ultrasound: Experience from 20 European registries. *Ultrasound Obstet Gynecol* 17:386, 2001.
- Heide H, Thomson J, Wharton G, et al: Poor sensitivity of routine fetal anomaly ultrasound screening for antenatal detection of atrioventricular septal defect. *Heart* 90:916, 2004.
- Allan L, Hornberger L, Sharland G (eds): *Textbook of Fetal Cardiology*. London, Greenwich Medical Media, 2000.
- Yagel S, Silverman N, Gembruch U (eds): *Fetal Cardiology*. London, Martin Dunitz, 2003.
- Centers for Disease Control and Prevention: Trends in infant mortality attributable to birth defects—United States, 1980-1995. *MMWR Morb Mortal Wkly Rep* 47:773, 1998.
- Ferencz C, Rubin JD, Mc Carter RJ, et al: Congenital heart disease: Prevalence at live birth. The Baltimore-Washington Infant Study. *Am J Epidemiol* 121:31, 1985.
- Hoffman J: Incidence of congenital heart disease: I. Postnatal incidence. *Pediatr Cardiol* 16:103, 1995.
- Hoffman J, Christianson R: Congenital heart disease in a cohort of 19,502 births with long-term follow-up. *Am J Cardiol* 42:641, 1978.
- Axt-Flidner R, Schwarze A, Smrcek J, et al: Isolated ventricular septal defects detected by color Doppler imaging: Evolution during fetal and first year of postnatal life. *Ultrasound Obstet Gynecol* 27:266, 2006.
- Smrcek J, Berg C, Geipel A, et al: Detection rate of early fetal echocardiography and in utero development of congenital heart defects. *J Ultrasound Med* 25:187, 2006.
- Trines J, Hornberger LK: Evolution of heart disease in utero. *Pediatr Cardiol* 25:287, 2004.

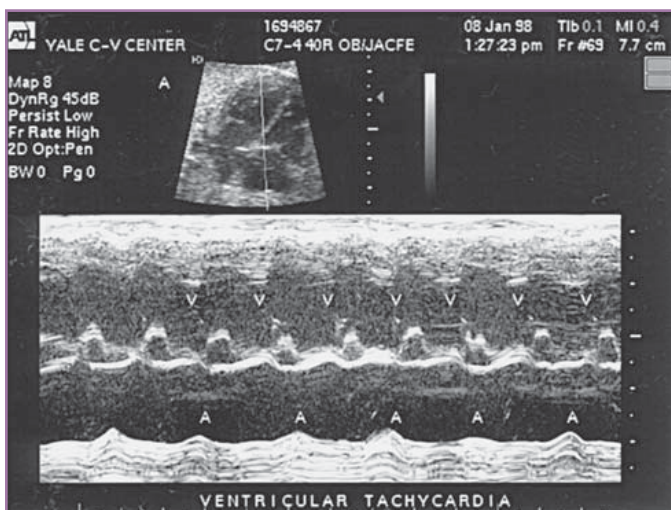


FIGURE 19-69 Fetal echocardiographic image of M-mode demonstration of ventricular tachycardia. Note atrioventricular dissociation, with ventricular rate faster than atrial rate. A, atrial contraction; V, ventricular contraction. (Image courtesy of Charles Kleinman, MD, Joshua Copel, MD, and Rodrigo Nehgme, MD.)

17. Weber H, Kleinman C, Hellenbrand W, et al: Development of a benign intrapericardial tumor between 20 and 40 weeks of gestation. *Pediatr Cardiol* 9:153, 1988.
18. Maeno Y, Kamenir S, Sinclair B, et al: Prenatal features of ductus arteriosus constriction and restrictive foramen ovale in d-transposition of the great arteries. *Circulation* 99:1209, 1999.
19. Stumfplén I, Stumfplén A, Wimmer M, et al: Effect of detailed fetal echocardiography as part of routine prenatal ultrasonographic screening on detection of congenital heart disease. *Lancet* 348:854, 1996.
20. Cooper M, Enderlein M, Dyson D, et al: Fetal echocardiography: Retrospective review of clinical experience and an evaluation of indications. *Obstet Gynecol* 86:577, 1995.
21. Small M, Copel JA: Indications for fetal echocardiography. *Pediatr Cardiol* 25:210, 2004.
22. Carvalho J: The fetal heart or the lymphatic system or . . . ? The quest for the etiology of increased nuchal translucency. *Ultrasound Obstet Gynecol* 25:215, 2005.
23. Jones K. Smith's Recognizable Patterns of Human Malformation, 6th ed. Philadelphia, Elsevier Saunders, 2006.
24. Gill HK, Splitt M, Sharland GK, et al: Patterns of recurrence of congenital heart disease: An analysis of 6,640 consecutive pregnancies evaluated by detailed fetal echocardiography. *J Am Coll Cardiol* 42:923, 2003.
25. Milerad J, Larson O, Hagberg C, et al: Associated malformations in infants with cleft lip and palate: A prospective, population-based study. *Pediatrics* 100:180, 1997.
26. Copel JA, Pulu G, Kleinman CS: Congenital heart disease and extracardiac anomalies: Associations and indications for fetal echocardiography. *Am J Obstet Gynecol* 154:1121, 1986.
27. Nora JJ, Nora AH: Maternal transmission of congenital heart diseases: New recurrence risk figures and the questions of cytoplasmic inheritance and vulnerability to teratogens. *Am J Cardiol* 59:459, 1987.
28. Allan L, Crawford D, Chita S, et al: Familial recurrence of congenital heart disease in a prospective series of mothers referred for fetal echocardiography. *Am J Cardiol* 58:334, 1986.
29. Zierler S: Maternal drugs and congenital heart disease. *Obstet Gynecol* 65:155, 1985.
30. Cooley WC, Graham JM Jr: Down syndrome: An update and review for the primary pediatrician. *Clin Pediatr* 30:233, 1991.
31. Boughman JA, Berg KA, Astemborski JA, et al: Familial risks of congenital heart defect in a population-based epidemiological study. *Am J Med Genet* 26:839, 1987.
32. Whittemore R, Wells J, Castellsague X: A second-generation study of 427 probands with congenital heart defects and their 837 children. *J Am Coll Cardiol* 23:1459, 1994.
33. Hyett J, Perdu M, Sharland G, et al: Using fetal nuchal translucency to screen for major congenital cardiac defects at 10-14 weeks of gestation: Population based cohort study. *BMJ* 318:81, 1999.
34. Burn J, Brennan P, Little J, et al: Recurrence risks in offspring of adults with major heart defects: Results from first cohort of British collaborative study. *Lancet* 351:311, 1998.
35. Van Marter L, Leviton A, Allred E, et al: Persistent pulmonary hypertension of the newborn and smoking and aspirin and nonsteroidal anti-inflammatory drug consumption during pregnancy. *Pediatrics* 97:658, 1996.
36. Becerra JE, Khoury MJ, Cordero JF, et al: Diabetes mellitus during pregnancy and the risks for specific birth defects: A population-based case control study. *Pediatrics* 85:1, 1990.
37. Sklansky M: Prenatal screening for congenital heart disease: A moving proposal. *J Ultrasound Med* 26:1, 2007.
38. Khoshnood B, Vigan C, Vodovar V, et al: Trends in prenatal diagnosis, pregnancy termination, and perinatal mortality of newborns with congenital heart disease in France, 1983-2000: A population-based evaluation. *Pediatrics* 115:95, 2005.
39. Franklin O, Burch M, Manning N, et al: Prenatal diagnosis of coarctation of the aorta improves survival and reduces morbidity. *Heart* 87:67, 2002.
40. Verheijen PM, Lisowski LA, Stoutenbeek P, et al: Prenatal diagnosis of congenital heart disease affects preoperative acidosis in the newborn infant. *J Thorac Cardiovasc Surg* 121:798, 2001.
41. Mahle W, Clancy R, McGaurn S, et al: Impact of prenatal diagnosis on survival and early neurologic morbidity in neonates with the hypoplastic left heart syndrome. *Pediatrics* 107:1277, 2001.
42. Kovalchin JP, Silverman NH: The impact of fetal echocardiography. *Pediatr Cardiol* 25:299, 2004.
43. Bonnet D, Coltri A, Butera G, et al: Detection of transposition of the great arteries in fetuses reduces neonatal morbidity and mortality. *Circulation* 99:916, 1999.
44. Meyer-Wittkopf M, Cooper S, Sholler G: Correlation between fetal cardiac diagnosis by obstetric and pediatric cardiologist sonographers and comparison with postnatal findings. *Ultrasound Obstet Gynecol* 17:392, 2001.
45. Copel JA, Pulu G, Green J, et al: Fetal echocardiographic screening for congenital heart disease: The importance of the four-chamber view. *Am J Obstet Gynecol* 157:648, 1987.
46. Allan LD, Crawford DC, Chita SK, et al: Prenatal screening for congenital heart disease. *BMJ* 292:1717, 1986.
47. DeVore GR: The prenatal diagnosis of congenital heart disease: A practical approach for the fetal sonographer. *J Clin Ultrasound* 13:229, 1985.
48. American Institute of Ultrasound in Medicine: AIUM Practice Guideline for the Performance of an Antepartum Obstetric Ultrasound Examination. Laurel, MD, AIUM, 2003.
49. American College of Obstetrics and Gynecology: ACOG Practice Bulletin No. 58: Ultrasonography in Pregnancy. *Obstet Gynecol* 104:1449, 2004.
50. Tegnander E, Eik-Nes SH, Johansen OJ, et al: Prenatal detection of heart defects at the routine fetal examination at 18 weeks in a non-selected population. *Ultrasound Obstet Gynecol* 5:373, 1995.
51. Crane JP, Lefevre ML, Winborn RC, et al: A randomized trial of prenatal ultrasonographic screening: Impact on the detection, management and outcome of anomalous fetuses. The RADIUS Study Group. *Am J Obstet Gynecol* 171:393, 1994.
52. Todros T, Faggiano F, Chiappa E, et al: Accuracy of routine ultrasonography in screening heart disease prenatally. *Prenat Diagn* 17:901, 1997.
53. DeVore GR, Horenstein J, Siassi B, et al: Fetal echocardiography: VII. Doppler color flow mapping: A new technique for the diagnosis of congenital heart disease. *Am J Obstet Gynecol* 156:1054, 1987.
54. Carvalho J, Mavrides E, Shinebourne E, et al: Improving the effectiveness of routine prenatal screening for major congenital heart defects. *Heart* 88:387, 2002.
55. Ogge G, Gaglioti P, Maccanti S, et al: Prenatal screening for congenital heart disease with four-chamber and outflow-tract views: A multicenter study. *Ultrasound Obstet Gynecol* 28:779, 2006.
56. Kirk JS, Riggs TW, Comstock CH, et al: Prenatal screening for cardiac anomalies: The value of routine addition of the aortic root to the four-chamber view. *Obstet Gynecol* 84:427, 1994.
57. Kirk JS, Comstock CH, Lee W, et al: Sonographic screening to detect fetal cardiac anomalies: A 5-year experience with 111 abnormal cases. *Obstet Gynecol* 89:227, 1997.
58. DeVore GR: The aortic and pulmonary outflow tract screening in the human fetus. *J Ultrasound Med* 11:345, 1992.
59. Bromley B, Estroff JA, Sanders SP, et al: Fetal echocardiography: Accuracy and limitations in a population at high and low risk for heart defects. *Am J Obstet Gynecol* 166:1473, 1992.
60. Sklansky M, Miller D, DeVore G, et al: Prenatal screening for congenital heart disease using real-time three-dimensional echocardiography and a novel "sweep volume" acquisition technique. *Ultrasound Obstet Gynecol* 25:435, 2005.
61. DeVore GR, Polanco B, Sklansky MS, et al: The "spin" technique: A new method for examination of the fetal outflow tracts using three-dimensional ultrasound. *Ultrasound Obstet Gynecol* 24:72, 2004.
62. Goncalves L, Lee W, Espinoza J, et al: Examination of the fetal heart by four-dimensional (4D) ultrasound with spatio-temporal image correlation (STIC). *Ultrasound Obstet Gynecol* 27:336, 2006.

63. Abuhamad A: Automated multiplanar imaging: A novel approach to ultrasonography. *J Ultrasound Med* 23:573, 2004.
64. Espinoza J, Kusanovic JP, Gonçalves LF, et al: A novel algorithm for comprehensive fetal echocardiography using 4-dimensional ultrasonography and tomographic imaging. *J Ultrasound Med* 25:947, 2006.
65. Wong S, Chan F, Cincotta B, et al: Factors influencing the prenatal detection of structural congenital heart diseases. *Ultrasound Obstet Gynecol* 21:19, 2003.
66. Sklansky MS, Nelson TR, Pretorius DH: Three-dimensional echocardiography: Gated versus nongated techniques. *J Ultrasound Med* 17:451, 1998.
67. Carvalho JS, Moscoso G, Tekay A, et al: Clinical impact of first and early second trimester fetal echocardiography on high risk pregnancies. *Heart* 90:921, 2004.
68. Haak MC, Twisk JW, Van Vugt JM: How successful is fetal echocardiographic examination in the first trimester of pregnancy? *Ultrasound Obstet Gynecol* 20:9, 2002.
69. Haak M, Van Vugt JMG: Echocardiography in early pregnancy: Review of literature. *J Ultrasound Med* 22:271, 2003.
70. Huggon IC, Ghi T, Cook AC, et al: Fetal cardiac abnormalities identified prior to 14 weeks gestation. *Ultrasound Obstet Gynecol* 20:22, 2002.
71. Dizon-Townson D, Dildy G, Clark S: A prospective evaluation of fetal pericardial fluid in 506 second-trimester low-risk pregnancies. *Obstet Gynecol* 90:958, 1997.
72. Smith R, Comstock C, Kirk J, et al: Ultrasonographic left cardiac axis deviation: A marker for fetal anomalies. *Obstet Gynecol* 85:187, 1995.
73. Respondek M, Respondek A, Huhta J, et al: 2D echocardiographic assessment of the fetal heart size in the 2nd and 3rd trimester of uncomplicated pregnancy. *Eur J Obstet Gynecol Reprod Biol* 44:185, 1992.
74. Kirk J, Comstock C, Lee W, et al: Fetal cardiac asymmetry: A marker for congenital heart disease. *Obstet Gynecol* 93:189, 1999.
75. Abuhamad A, Falkensammer P, Zhao Y: Automated sonography: Defining the spatial relationship of standard diagnostic fetal cardiac planes in the second trimester of pregnancy. *J Ultrasound Med* 26:501, 2007.
76. Michailidis GC, Simpson JM, Karidas C, et al: Detailed three-dimensional fetal echocardiography facilitated by an internet link. *Ultrasound Obstet Gynecol* 18:325, 2001.
77. DeVore GR, Polanko B: Tomographic ultrasound imaging of the fetal heart: A new technique for identifying normal and abnormal cardiac anatomy. *J Ultrasound Med* 24:1685, 2005.
78. Rychik J, Ayres N, Cuneo B, et al: American Society of Echocardiography Guidelines and Standards for Performance of the Fetal Echocardiogram. *J Am Soc Echocardiogr* 17:803, 2004.
79. Allan LD, Chita SK, Sharland GK, et al: The accuracy of fetal echocardiography in the diagnosis of congenital heart disease. *Int J Cardiol* 25:279, 1989.
80. Allan L, Sharland G, Milburn A, et al: Prospective diagnosis of 1,006 consecutive cases of congenital heart disease in the fetus. *J Am Coll Cardiol* 23:1452, 1994.
81. Hornberger LK, Sanders SP, Sahn DJ, et al: In utero pulmonary artery and aortic growth and potential for progression of pulmonary outflow tract obstruction in tetralogy of Fallot. *J Am Coll Cardiol* 25:739, 1995.
82. Hornberger LK, Sanders SP, Rein AJ, et al: Left heart obstructive lesions and left ventricular growth in the midtrimester fetus: A longitudinal study. *Circulation* 92:1531, 1995.
83. Lombardi C, Bellotti M, Fesslova V, et al: Fetal echocardiography at the time of the nuchal translucency scan. *Ultrasound Obstet Gynecol* 29:249, 2007.
84. Del Rio M, Martinez J, Figueras F, et al: Reference ranges for Doppler parameters of the fetal aortic isthmus during the second half of pregnancy. *Ultrasound Obstet Gynecol* 28:71, 2006.
85. Allan L, Dangel J, Fesslova V, et al: Recommendations for the practice of fetal cardiology in Europe. *Cardiol Young* 14:109, 2004.
86. Michelfelder E: Doppler echocardiographic characterization of the fetus in distress. *Prog Pediatr Cardiol* 22:31, 2006.
87. Eidem B, Edwards J, Cetta F: Quantitative assessment of fetal ventricular function: Establishing normal values of the myocardial performance index in the fetus. *Echocardiography* 18:9, 2001.
88. Mori Y, Rice M, McDonald R, et al: Evaluation of systolic and diastolic ventricular performance of the right ventricle in fetuses with ductal constriction using the Doppler Tei index. *Am J Cardiol* 88:1173, 2001.
89. Larsen L, Peterson O, Norrild K, et al: Strain rate derived from color Doppler myocardial imaging for assessment of fetal cardiac function. *Ultrasound Obstet Gynecol* 27:210, 2006.
90. Mari G, Uerpaiojkit B, Copel J: Abdominal venous system in the normal fetus. *Obstet Gynecol* 86:729, 1995.
91. Better D, Kaufman S, Allan L: The normal pattern of pulmonary venous flow on pulsed Doppler examination of the human fetus. *J Am Soc Echocardiogr* 9:281, 1996.
92. Harada K, Rice M, Shiota T, et al: Gestational age- and growth-related alterations in fetal right and left ventricular diastolic filling patterns. *Am J Cardiol* 79:173, 1997.
93. Weiner Z, Efrat Z, Zimmer E, et al: Fetal atrioventricular blood flow throughout gestation. *Am J Cardiol* 80:658, 1997.
94. Splunder P, Stijnen T, Wladimiroff J: Fetal atrioventricular flow-velocity waveforms and their relation to arterial and venous flow-velocity waveforms at 8 to 20 weeks of gestation. *Circulation* 94:1372, 1996.
95. Schneider C, McCrindle B, Carvalho S, et al: Development of Z-scores for fetal cardiac dimensions from echocardiography. *Ultrasound Obstet Gynecol* 26:599, 2005.
96. DeVore G: The use of Z-scores in the analysis of fetal cardiac dimensions. *Ultrasound Obstet Gynecol* 26:596, 2005.
97. Firpo C, Hoffman J, Silverman N: Evaluation of fetal heart dimensions from 12 weeks to term. *Am J Cardiol* 87:594, 2001.
98. Hornberger LK, Weintraub RG, Pesonen E, et al: Echocardiographic study of the morphology and growth of the aortic arch in the human fetus. *Circulation* 86:741, 1992.
99. Sharland GK, Allan LD: Normal fetal cardiac measurements derived by cross-sectional echocardiography. *Ultrasound Obstet Gynecol* 2:175, 1992.
100. Tan J, Silverman NH, Hoffman JJ, et al: Cardiac dimensions determined by cross-sectional echocardiography in the normal human fetus from 18 weeks to term. *Am J Cardiol* 70:1459, 1992.
101. Rein A, O'Donnell C, Geva T, et al: Use of tissue velocity imaging in the diagnosis of fetal cardiac arrhythmias. *Circulation* 106:1827, 2002.
102. Paladini D, Lamberti A, Teodoro A, et al: Tissue Doppler imaging of the fetal heart. *Ultrasound Obstet Gynecol* 16:530, 2000.
103. Huhta JC: Guidelines for the evaluation of heart failure in the fetus with or without hydrops. *Pediatr Cardiol* 25:274, 2004.
104. Allan L: Technique of fetal echocardiography. *Pediatr Cardiol* 25:223, 2004.
105. DeVore G: Trisomy 21: 91% Detection rate using second-trimester ultrasound markers. *Ultrasound Obstet Gynecol* 16:133, 2000.
106. Yeager S, Parness I, Spevak P, et al: Prenatal echocardiographic diagnosis of pulmonary and systemic venous anomalies. *Am Heart J* 128:397, 1994.
107. Chaoui R, Heling K, Kalache K: Caliber of the coronary sinus in fetuses with cardiac defects with and without left persistent superior vena cava and in growth-restricted fetuses with heart-sparing effect. *Prenat Diagn* 23:552, 2003.
108. Agnoletti G, Anecchino F, Preda L, et al: Persistence of the left superior caval vein: Can it potentiate obstructive lesions of the left ventricle? *Cardiol Young* 9:285, 1999.
109. Berg C, Knuppel M, Geipel A, et al: Prenatal diagnosis of persistent left superior vena cava and its associated congenital anomalies. *Ultrasound Obstet Gynecol* 27:274, 2006.
110. Atkinson D, Drant S: Diagnosis of heterotaxy syndrome by fetal echocardiography. *Am J Cardiol* 82:1147, 1998.
111. Messing B, Porat S, Imbar T, et al: Mild tricuspid regurgitation: A benign fetal finding at various stages of pregnancy. *Ultrasound Obstet Gynecol* 26:60, 2005.

112. Respondek M, Kammermeier M, Ludomirsky A, et al: The prevalence and clinical significance of fetal tricuspid valve regurgitation with normal heart anatomy. *Am J Obstet Gynecol* 171:1265, 1994.
113. Nii M, Roman K, Kingdom J, et al: Assessment of the evolution of normal fetal diastolic function during mid and late gestation by spectral Doppler tissue echocardiography. *J Am Soc Echocardiogr* 19:1431, 2006.
114. Pedra S, Smallhorn J, Ryan G, et al: Fetal cardiomyopathies: Pathogenic mechanisms, hemodynamic findings, and clinical outcome. *Circulation* 106:585, 2002.
115. Barsoom M, Feldman D, Borgida A, et al: Is an isolated fetal echogenic focus an indication for fetal echocardiography? *J Ultrasound Med* 20:1043, 2001.
116. Doubilet P, Copel J, Benson C, et al: Choroid plexus cyst and echogenic intracardiac focus in women at low risk for chromosomal anomalies: The obligation to inform the mother. *J Ultrasound Med* 23:88, 2004.
117. Filly R, Benacerraf B, Nyberg D, et al: Choroid plexus cyst and echogenic intracardiac focus in women at low risk for chromosomal anomalies. *J Ultrasound Med* 23:447, 2004.
118. Sotiriadis A, Makrydimas G, Ioannides J: Diagnostic performance of intracardiac echogenic foci for Down syndrome: A meta-analysis. *Obstet Gynecol* 101:1009, 2003.
119. Vibhakar N, Budorick N, Scioscia A, et al: Prevalence of aneuploidy with a cardiac intraventricular echogenic focus in an at-risk patient population. *J Ultrasound Med* 18:265, 1999.
120. Sokol J, Shimizu N, Bohn D, et al: Fetal pulmonary artery diameter measurements as a predictor of morbidity in antenatally diagnosed congenital diaphragmatic hernia: A prospective study. *Am J Obstet Gynecol* 195:470, 2006.
121. Tulzer G, Gudmundsson S, Tews G, et al: Incidence of indomethacin-induced human fetal ductal constriction. *J Matern Fetal Invest* 1:267, 1992.
122. Tulzer G, Gudmundsson S, Sharkey AM, et al: Doppler echocardiography of fetal ductus arteriosus constriction versus increased right ventricular output. *J Am Coll Cardiol* 18:532, 1991.
123. Kleinman C, Donnerstein R, DeVore G, et al: Fetal echocardiography for evaluation of in utero congestive heart failure. *N Engl J Med* 306:568, 1982.
124. Hecher K, Campbell S, Doyle P, et al: Assessment of fetal compromise by Doppler ultrasound investigation of the fetal circulation. *Circulation* 91:129, 1995.
125. Rychik J: Fetal cardiovascular physiology. *Pediatr Cardiol* 25:201, 2004.
126. Nelson T, Pretorius D, Sklansky M, et al: Three-dimensional echocardiographic evaluation of fetal heart anatomy and function: Acquisition, analysis and display. *J Ultrasound Med* 15:1, 1996.
127. Deng J, Gardener JE, Rodeck CH, et al: Fetal echocardiography in three and four dimensions. *Ultrasound Med Biol* 22:979, 1996.
128. Sklansky MS, Nelson TR, Pretorius DH: Usefulness of gated three-dimensional fetal echocardiography to reconstruct and display structures not visualized with two-dimensional imaging. *Am J Cardiol* 80:665, 1997.
129. DeVore GR, Falkensammer P, Sklansky MS, et al: Spatio-temporal image correlation (STIC): A new technology for evaluation of the fetal heart. *Ultrasound Obstet Gynecol* 22:380, 2003.
130. Gonçalves LF, Lee W, Chaiworapongsa T, et al: Four-dimensional ultrasonography of the fetal heart with spatiotemporal image correlation. *Am J Obstet Gynecol* 189:1792, 2003.
131. Deng J, Rodeck C: Current applications of fetal cardiac imaging technology. *Curr Opin Obstet Gynecol* 18:177, 2006.
132. Maulik D, Nanda NC, Singh V, et al: Live three-dimensional echocardiography of the human fetus. *Echocardiography* 20:715, 2003.
133. Deng J, Sullivan ID, Yates R, et al: Real-time three-dimensional fetal echocardiography: optimal imaging windows. *Ultrasound Med Biol* 28:1099, 2002.
134. Viñals F, Poblete P, Giuliano A: Spatio-temporal image correlation (STIC): A new tool for the prenatal screening of congenital heart defects. *Ultrasound Obstet Gynecol* 22:388, 2003.
135. Chaoui R, Hoffmann J, Heling KS: Three-dimensional (3D) and 4D color Doppler fetal echocardiography using spatiotemporal image correlation (STIC). *Ultrasound Obstet Gynecol* 23:535, 2004.
136. Sklansky MS, Nelson T, Strachan M, et al: Real-time three-dimensional fetal echocardiography: Initial feasibility study. *J Ultrasound Med* 18:745, 1999.
137. Sklansky MS, DeVore GR, Wong PC: Real-time 3-dimensional fetal echocardiography with an instantaneous volume-rendered display: Early description and pictorial essay. *J Ultrasound Med* 23:283, 2004.
138. Gonçalves LF, Romero R, Espinoza J, et al: Four-dimensional ultrasonography of the fetal heart using color Doppler spatiotemporal image correlation. *J Ultrasound Med* 23:473, 2004.
139. Schindera ST, Mehwald PS, Sahn DJ, et al: Accuracy of real-time three-dimensional echocardiography for quantifying right ventricular volume. *J Ultrasound Med* 21:1069, 2002.
140. DeVore G, Sklansky M: Three-dimensional imaging of the fetal heart: Current applications and future directions. *Progr Pediatr Cardiol* 22:9, 2006.
141. Meyer-Wittkopf M, Cole A, Cooper SG, et al: Three-dimensional quantitative echocardiographic assessment of ventricular volume in healthy human fetuses and in fetuses with congenital heart disease. *J Ultrasound Med* 20:317, 2001.
142. Deng J, Ruff C, Linney A, et al: Simultaneous use of two ultrasound scanners for motion-gated three-dimensional fetal echocardiography. *Ultrasound Med Biol* 26:1021, 2000.
143. Yagel S, Benachi A, Bonnet D, et al: Rendering in fetal cardiac scanning: The intracardiac septa and the coronal atrioventricular valve planes. *Ultrasound Obstet Gynecol* 28:266, 2006.
144. Volpe P, Campobasso G, Stanziano A, et al: Novel application of 4D sonography with B-flow imaging and spatio-temporal image correlation (STIC) in the assessment of the anatomy of pulmonary arteries in fetuses with pulmonary atresia and ventricular septal defect. *Ultrasound Obstet Gynecol* 28:40, 2006.
145. Acar P, Dulac Y, Taktak A, et al: Real-time three-dimensional fetal echocardiography using matrix probe. *Prenat Diagn* 25:370, 2005.
146. Scharf A, Geka F, Steinborn A, et al: 3D real-time imaging of the fetal heart. *Fetal Diagn Ther* 15:267, 2000.
147. Meyer-Wittkopf M, Rappe N, Sierra R, et al: Three-dimensional (3-D) ultrasonography for obtaining the four and five-chamber view: Comparison with cross-sectional (2-D) fetal sonographic screening. *Ultrasound Obstet Gynecol* 15:397, 2000.
148. Hejmadi A, Corbett V, Carpenter N, et al: Fetal ventricular mass determination on three-dimensional echocardiography: Studies in normal fetuses and validation experiments. *Circulation* 110:1054, 2004.
149. Chang F, Hsu K, Ko H, et al: Fetal heart volume assessment by three-dimensional ultrasound. *Ultrasound Obstet Gynecol* 9:42, 1997.
150. Moore K, Persaud T: *The Developing Human: Clinically Oriented Embryology*, 6th ed. Philadelphia, Saunders, 1998.
151. Abdulla R, Blew G, Holterman M: *Cardiovascular embryology*. *Pediatr Cardiol* 25:191, 2004.
152. Allen H, Gutgesell H, Clark E, et al (eds): *Moss and Adams' Heart Disease in Infants, Children and Adolescents Including the Fetus and Young Adult*, 6th ed. Philadelphia, Lippincott Williams & Wilkins, 2001.
153. Keane J, Lock J, Fyler D, et al (eds): *Nadas' Pediatric Cardiology*, 2nd ed. Philadelphia, Saunders, 2006.
154. Fasouliotis S, Achiron R, Kivilevitch Z, et al: The human fetal venous system: Normal embryologic, anatomic, and physiologic characteristics and developmental abnormalities. *J Ultrasound Med* 21:1145, 2002.
155. Lai W: Prenatal diagnosis of abnormal persistence of the right or left umbilical vein: Report of 4 cases and literature review. *J Am Soc Echocardiogr* 11:905, 1998.
156. Kirsch C, Feldstein V, Goldstein R, et al: Persistent intrahepatic right umbilical vein: A prenatal sonographic series without significant anomalies. *J Ultrasound Med* 15:371, 1996.
157. Lim J, McCrindle B, Smallhorn J, et al: Clinical features, management, and outcome of children with fetal and postnatal diagnoses of isomerism syndromes. *Circulation* 112:2454, 2005.

158. Michailidis G, Simpson J, Tulloh R, Economides D: Retrospective prenatal diagnosis of scimitar syndrome aided by three-dimensional power Doppler imaging. *Ultrasound Obstet Gynecol* 17:449, 2001.
159. Patel C, Lane J, Spector M, et al: Totally anomalous pulmonary venous connection and complex congenital heart disease. *J Ultrasound Med* 24:1191, 2005.
160. Patel C, Lane J, Sallee D: In utero diagnosis of isolated obstructed supra-cardiac total anomalous pulmonary venous connection. *J Ultrasound Med* 27:32, 2002.
161. Allan L, Sharland G: The echocardiographic diagnosis of totally anomalous pulmonary venous connection in the fetus. *Heart* 85:434, 2001.
162. Friedberg M, Kim N, Silverman N: Atrioventricular septal defect recently diagnosed by fetal echocardiography: Echocardiographic features, associated anomalies, and outcomes. *Congenit Heart Dis* 2:110, 2007.
163. Huggon I, Cook A, Smeeton N, et al: Atrioventricular septal defects diagnosed in fetal life: Associated cardiac and extra-cardiac abnormalities and outcome. *J Am Coll Cardiol* 36:593, 2000.
164. Hornberger L, Sahn D, Kleinman C, et al: Tricuspid valve disease with significant tricuspid insufficiency in the fetus: Diagnosis and outcome. *J Am Coll Cardiol* 17:167, 1991.
165. Sharland G, Chita S, Allan L: Tricuspid valve dysplasia or displacement in intrauterine life. *J Am Coll Cardiol* 17:944, 1991.
166. Tongsong T, Sittiwangkul R, Wanapirak C, et al: Prenatal diagnosis of isolated tricuspid valve atresia. *J Ultrasound Med* 23:945, 2004.
167. Peterson R, Levi D, Williams R, et al: Echocardiographic predictors of outcome in fetuses with pulmonary atresia with intact ventricular septum. *J Am Soc Echocardiogr* 19:1393, 2006.
168. Salvin J, McElhinney D, Colan S, et al: Fetal tricuspid valve size and growth as predictors of outcome in pulmonary atresia with intact ventricular septum. *Pediatrics* 118:e415, 2006.
169. Mahle W, Clancy R, Moss E, et al: Neurodevelopmental outcome and lifestyle assessment in school-aged and adolescent children with hypoplastic left heart syndrome. *Pediatrics* 105:1082, 2000.
170. Tworetzky W, Wilkins-Haug L, Jennings RW, et al: Balloon dilation of severe aortic stenosis in the fetus. *Circulation* 11:2125, 2004.
171. Marshall A, van der Velde M, Tworetzky W, et al: Creation of an atrial septal defect in utero for fetuses with hypoplastic left heart syndrome and intact or highly restrictive atrial septum. *Circulation* 110:25, 2004.
172. Chang R-K, Chen A, Klitzner T: Clinical management of infants with hypoplastic left heart syndrome in the United States, 1988-1997. *Pediatrics* 110:292, 2002.
173. Byrne P, Murphy A: Informed consent and hypoplastic left heart syndrome. *Acta Paediatrica* 94:1171, 2005.
174. Cohen M, Marino B, McElhinney D, et al: Neo-aortic root dilation and valve regurgitation up to 21 years after staged reconstruction for hypoplastic left heart syndrome. *J Am Coll Cardiol* 42:533, 2003.
175. Makikallio K, McElhinney D, Levine J, et al: Fetal aortic valve stenosis and the evolution of hypoplastic left heart syndrome: Patient selection for fetal intervention. *Circulation* 113:1401, 2006.
176. Head C, Jowett V, Sharland G, et al: Timing of presentation and postnatal outcome of infants suspected of having coarctation of the aorta during fetal life. *Heart* 91:1070, 2005.
177. Sharland G, Chan K-Y, Allan L: Coarctation of the aorta: Difficulties in prenatal diagnosis. *Br Heart J* 71:70, 1994.
178. Hornberger L, Sahn D, Kleinman C, et al: Antenatal diagnosis of coarctation of the aorta: A multicenter experience. *J Am Coll Cardiol* 23:417, 1994.
179. Botto LD, May K, Fernhoff PM, et al: A population-based study of the 22q11.2 deletion: Phenotype, incidence, and contribution to major birth defects in the population. *Pediatrics* 112:101, 2003.
180. Tometzki A, Suda K, Kohl T, et al: Accuracy of prenatal echocardiographic diagnosis and prognosis of fetuses with conotruncal anomalies. *J Am Coll Cardiol* 33:1696, 1999.
181. Lee W, Smith R, Comstock C, et al: Tetralogy of Fallot: Prenatal diagnosis and postnatal survival. *Obstet Gynecol* 86:583, 1995.
182. Moon-Grady A, Tacy T, Brook M, et al: Value of clinical and echocardiographic features in predicting outcome in the fetus, infant, and child with tetralogy of Fallot with absent pulmonary valve complex. *Am J Cardiol* 89:1280, 2002.
183. Razavi R, Sharland G, Simpson J: Prenatal diagnosis by echocardiogram and outcome of absent pulmonary valve syndrome. *Am J Cardiol* 91:429, 2003.
184. Galindo A, Gutierrez-Larraya F, Martinez J, et al: Prenatal diagnosis and outcome for fetuses with congenital absence of the pulmonary valve. *Ultrasound Obstet Gynecol* 28:32, 2006.
185. Gelehrter S, Owens S, Russell M, et al: Accuracy of the fetal echocardiogram in double-outlet right ventricle. *Congenit Heart Dis* 2:32, 2007.
186. Donofrio M: Premature closure of the foramen ovale and ductus arteriosus in a fetus with transposition of the great arteries. *Circulation* 105:e65, 2002.
187. Paladini D, Volpe P, Marasini M, et al: Diagnosis, characterization and outcome of congenitally corrected transposition of the great arteries in the fetus: A multicenter series of 30 cases. *Ultrasound Obstet Gynecol* 27:281, 2006.
188. Sharland G, Tingay R, Jones A, et al: Atrioventricular and ventriculoarterial discordance (congenitally corrected transposition of the great arteries): Echocardiographic features, associations, and outcome in 34 fetuses. *Heart* 91:1453, 2005.
189. Volpe P, Paladini D, Marasini M, et al: Common arterial trunk in the fetus: Characteristics, associations, and outcome in a multicenter series of 23. *Heart* 89:1437, 2003.
190. Duke C, Sharland G, Jones A, et al: Echocardiographic features and outcome of truncus arteriosus diagnosed during fetal life. *Am J Cardiol* 88:1379, 2001.
191. Isaacs H Jr: Fetal and neonatal tumors. *Pediatr Cardiol* 25:252, 2004.
192. Holley D, Martin G, Brenner J, et al: Diagnosis and management of fetal cardiac tumors: A multicenter experience and review of published papers. *J Am Coll Cardiol* 26:516, 1995.
193. Tworetzky W, McElhinney D, Margossian R, et al: Association between cardiac tumors and tuberous sclerosis in the fetus and neonate. *Am J Cardiol* 92:487, 2003.
194. Bader R, Chitayat D, Kelly E, et al: Fetal rhabdomyoma: Prenatal diagnosis, clinical outcome, and incidence of associated tuberous sclerosis complex. *J Pediatr* 143:620, 2003.
195. Sklansky M, Greenberg M, Lucas V, et al: Intrapericardial teratoma in a twin fetus: Diagnosis and management. *Obstet Gynecol* 89:807, 1997.
196. Kleinman CS, Nehgme RA: Cardiac arrhythmias in the human fetus. *Pediatr Cardiol* 25:234, 2004.
197. Kleinman C, Nehgme R, Copel J: Fetal cardiac arrhythmias: Diagnosis and therapy. In Creasy R, Resnik R, Iams J (eds): *Maternal-Fetal Medicine*, 5th ed. Philadelphia, Saunders, 2003.
198. Simpson J: Fetal arrhythmias. *Ultrasound Obstet Gynecol* 27:599, 2006.
199. Respondek M, Wloch A, Kaczmarek P, et al: Diagnostic and perinatal management of fetal extrasystole. *Pediatr Cardiol* 18:361, 1997.
200. Strasburger J, Huhta J, Carpenter R, et al: Doppler echocardiography in the diagnosis and management of persistent fetal arrhythmias. *J Am Coll Cardiol* 7:1386, 1986.
201. Kleinman C, Copel J, Hobbins J: Combined echocardiographic and Doppler assessment of fetal congenital atrioventricular block. *BJOG* 94:967, 1987.
202. Jeaggi E, Fouron J, Fournier A, et al: Ventriculo-atrial time interval measured on M-mode echocardiography: A determining element in diagnosis, treatment, and prognosis of fetal supraventricular tachycardia. *Heart* 79:582, 1998.
203. Hofbeck M, Ulmer H, Beinder E, et al: Prenatal findings in patients with prolonged QT interval in the neonatal period. *Heart* 77:198, 1997.
204. Oudijk MA, Michon MM, Kleinman CS, et al: Sotalol in the treatment of fetal dysrhythmias. *Circulation* 101:2721, 2000.
205. Schmidt LG, Ulmer HE, Silverman NH, et al: Perinatal outcome of fetal complete atrioventricular block: A multicenter experience. *J Am Coll Cardiol* 91:1360, 1991.
206. Buyon JP, Clancey R, Di Donato F, et al: Cardiac 5-HT serotonergic receptors, 52KD SSA/Ro and autoimmune-associated congenital heart block. *J Autoimmun* 19:79, 2002.

207. Buyon JP, Hiebert R, Copel JA, et al: Autoimmune-associated congenital heart block: Mortality, morbidity and recurrence rates obtained from a national neonatal lupus registry. *J Am Coll Cardiol* 31:165, 1998.
208. Nield LE, Silverman ED, Smallhorn JF, et al: Endocardial fibroelastosis associated with maternal anti-Ro and anti-La antibodies in the absence of atrioventricular block. *J Am Coll Cardiol* 40:796, 2002.
209. Jaeggi ET, Fouron JC, Silverman ED, et al: Transplacental fetal treatment improves the outcome of prenatally diagnosed complete atrioventricular block without structural heart disease. *Circulation* 110:1542, 2004.
210. Copel J, Buyon J, Kleinman C: Successful in utero therapy of fetal heart block. *Am J Obstet Gynecol* 173:1384, 1995.
211. Groves AM, Allan LD, Rosenthal E: Therapeutic trial of sympathomimetics in three cases of complete heart block in the fetus. *Circulation* 92:3394, 1995.
212. Brucato A, Frassi M, Franceschini F, et al: Risk of congenital complete heart block in newborns of mothers with anti-Ro/SSA antibodies detected by counterimmunoelectrophoresis: A prospective study of 100 women. *Arthritis Rheum* 44:1832, 2001.
213. Glickstein J, Buyon J, Friedman D: Pulsed Doppler echocardiographic assessment of the fetal PR interval. *Am J Cardiol* 86:236, 2000.
214. Bergman G, Jacobsson L, Wahren-Herlenius M, et al: Doppler echocardiographic and electrocardiographic atrioventricular time intervals in newborn infants: Evaluation of techniques for surveillance of fetuses at risk for congenital heart block. *Ultrasound Obstet Gynecol* 28:57, 2006.
215. Jaeggi E, Hamilton R, Silverman E, et al: Outcome of children with fetal, neonatal or childhood diagnosis of isolated congenital atrioventricular block. *J Am Coll Cardiol* 39:130, 2002.
216. Saleeb S, Copel J, Friedman D, et al: Comparison of treatment with fluorinated glucocorticoids to the natural history of autoantibody-associated congenital heart block: Retrospective review of the Research Registry for Neonatal Lupus. *Arthritis Rheum* 42:2335, 1999.
217. Simpson LL, Marx GR, D'Alton ME: Supraventricular tachycardia in the fetus: Conservative management in the absence of hemodynamic compromise. *J Ultrasound Med* 16:459, 1997.
218. Cuneo BF, Strasburger JF: Management strategy for fetal tachycardia. *Obstet Gynecol* 96:575, 2000.
219. Van Engelen A, Weijtens O, Brenner J, et al: Management outcome and follow-up of fetal tachycardia. *J Am Coll Cardiol* 24:1371, 1994.
220. Lupoglazoff J, Jacoz-Aigrain E, Guyot B, et al: Endogenous digoxin-like immunoreactivity during pregnancy and at birth. *Br J Clin Pharmacol* 35:251, 1993.
221. Allan L, Chita S, Sharland G, et al: Flecainide in the treatment of fetal tachycardia. *Br Heart J* 65:46, 1991.
222. Strasburger J, Cuneo B, Michon M, et al: Amiodarone therapy for drug-refractory fetal tachycardia. *Circulation* 109:375, 2004.
223. Lisowski L, Verheijen P, Benatar A, et al: Atrial flutter in the perinatal age group: Diagnosis, management and outcome. *J Am Coll Cardiol* 35:771, 2000.
224. Texter KM, Kertesz N, Friedman R, et al: Atrial flutter in infants. *J Am Coll Cardiol* 48:1040, 2006.

This page intentionally left blank